ORIGINAL RESEARCH

Assessment of Restoration of Nasal Volume and Nasal Area in Patients with Maxillectomy Defects Rehabilitated with Obturator Prosthesis Using Acoustic Rhinometry: A Preliminary Study

Kirandeep Singh[1], Vijaya K Rajamani[2], EM Gowda[3], NSC Charles[4]

Received on: 22 December 2022; *Accepted on:* 11 January 2023; *Published on:* 03 May 2023

Abstract

Purpose: To evaluate the nasal volume and nasal area using acoustic rhinometry in patients with maxillectomy defects rehabilitated with obturator prosthesis.

Materials and methods: A total of eight patients having maxillectomy defects rehabilitated with obturator prosthesis were assessed for nasal cross-sectional area (CSA) and nasal volume using Eccovision Acoustic Rhinometer system. The average nasal area and nasal volume in patients with maxillectomy defects were compared before and after rehabilitation with an obturator prosthesis. The statistical analysis was done using a paired *t*-test to compare nasal area and nasal volume before and after rehabilitation.

Results: The mean ± standard deviation (SD) values of the nasal area and nasal volume showed statistically significant difference when compared with and without obturator prosthesis. The mean right nasal CSA before rehabilitation was 0.806 ± 0.158 mm^2 and it significantly reduced to 0.218 ± 0.039 mm^2 after the use of an obturator prosthesis ($p < 0.0001$). Similarly, the right nasal volume, which was 8.302 ± 1.229 cm^3 significantly improved to 3.281 ± 0.44 cm^3 after rehabilitation with obturator prosthesis ($p < 0.0001$). The average left nasal CSA and nasal volume were compared with and without prosthesis and they too showed a significant improvement from 0.677 ± 0.281 mm^2 to 0.215 ± 0.038 mm^2 and 8.81 ± 0.982 cm^3 to 3.65 ±, 0.300 cm^3, respectively ($p < 0.0001$).

Conclusion: The assessment of pretreatment (postmaxillectomy) and posttreatment (postrehabilitation with obturator prosthesis) values of nasal volume and nasal area, when compared with standard values, clearly indicated that obturator prosthesis restored the nasal volume and area to the near normal.

Keywords: Acoustic rhinometry, Maxillectomy, Nasal area, Nasal volume, Obturator prosthesis.

International Journal of Prosthodontics & Restorative Dentistry (2022): 10.5005/jp-journals-10019-1376

Introduction

Maxillectomy defects can be congenital or acquired. Such defects often result in the communication of the oral cavity with maxillary sinus and nasal cavity.[1] This communication leads to an increase in nasal volume due to the removal of adjoining structures. Acquired defects created by surgical excision of the maxilla are rehabilitated by obturator prosthesis.[2] This helps in the rehabilitation of lost structures, restoration of occlusion, correction of speech, and restoration of the nasal volume to near-normal values.

The superior extent of the prosthesis is the most important aspect of the obturator prosthesis, which helps in the restoration of the nasal volume and separates the oral cavity from the nasal cavity.[3] Underextension of the obturator will not be able to restore the nasal volume and overextension of the prosthesis will impinge the remaining soft tissues and affects the retention of the prosthesis. The obturator prosthesis should be able to restore the lost anatomy of the nasal structures and the normal area and volume of the nasal cavity. This can be assessed either subjectively based on the symptoms of the patient or objectively by measuring the CSAs or volume of a nasal cavity by imaging, such as magnetic resonance imaging (MRI) or computed tomography (CT). These available radiographic imaging techniques have their own limitations.[4,5]

To avoid such limitations, this study was conducted to assess the restoration of nasal volume and nasal CSA in patients with maxillectomy defects rehabilitated with an obturator prosthesis using acoustic rhinometery.

[1–3]Department of Dental Surgery & Oral Health Sciences, Armed Forces Medical College, Pune, Maharashtra, India

[4]Military Dental Centre, Roorkee, Uttarakhand, India

Corresponding Author: Vijaya K Rajamani, Department of Dental Surgery & Oral Health Sciences, Armed Forces Medical College, Pune, Maharashtra, India, Phone: +91 9674066444, e-mail: dentvk@gmail.com

How to cite this article: Singh K, Rajamani VK, Gowda EM, *et al.* Assessment of Restoration of Nasal Volume and Nasal Area in Patients with Maxillectomy Defects Rehabilitated with Obturator Prosthesis Using Acoustic Rhinometry: A Preliminary Study. Int J Prosthodont Restor Dent 2022;12(4):181–184.

Source of support: Nil

Conflict of interest: None

Materials and Methods

This preliminary study was conducted at the Department of Prosthodontics and Crown and Bridge of a tertiary care hospital, Pune, Maharashtra, India. A sample of eight patients with maxillectomy defects were selected using Statistical Package for the Social Sciences (SPSS) software (IBM Corp. Released 2011.

IBM SPSS Statistics for Windows, version 20.0. Armonk, New York, United States of America—IBM Corp.) for this preliminary study. Ethical clearance approval form for the study was taken from the Institutional Ethical Committee vide no. IEC/Dept/Dental/2019/DL-5, dated 10th April 2019. The patients were explained the procedure in detail and written informed consent was taken from the patients.

The inclusion criteria include patients aged 45–60 years with Aramany class IV maxillectomy defect rehabilitated with definitive obturator prosthesis and those with no signs of recurrence of the active infection were included in the study. Patients who had been using a definitive hollow bulb obturator prosthesis for >1 week without any postinsertion problems were included in the study. The patients with congenital cleft palate, active inflammation, such as acute rhinitis and acute nasal swelling, signs of recurrence of the tumor, orofacial trauma, and syndromic cases were excluded from the study.

The methodology described by Gomes et al.,[6] utilizing Eccovision Acoustic Rhinometer (Sleep Group Solutions, Hollywood, Florida, United States of America) system was used for rhinometric assessment. The system consists of Eccovision control unit, customized hardware and software, wave tube, calibration tube, and silicone nose tips. The examination procedure involved placing the proximal end of the rhinometer tube, which is covered with a silicone nose piece over one of the nostrils. The rhinometry tube was kept parallel to the dorsum of the nose to avoid errors (Fig. 1). Placement of rhinometer tube should not deform the nose and care should be taken that the individual is not wearing any spectacles or nose ring, as the pressure exerted by spectacles and nose ring can result in faulty readings. In order to avoid errors in values, a single operator performed the procedure. The system delivered 10 sound pulses of 0.5 seconds each and the average of the 10 repetitions was calculated by software to measure the nasal CSA and the volume. The procedure was performed on the right and left nostrils with and without obturator prosthesis for each patient.

The data was obtained in the form of a graphical representation and values for both nasal volume and CSA. The data was compared for both the nostrils with and without obturator prosthesis (Fig. 2). Data retrieved was subjected to statistical analysis. Data was analyzed and summarized as mean reading with SD using SPSS software (IBM Corp. Released 2011. IBM SPSS Statistics for Windows, version 20.0. Armonk, New York, United States of America—IBM Corp.). The paired '*t*' test was used to compare the nasal area and the nasal volume before and after rehabilitation. $p < 0.05$ was considered significant.

Fig. 1: Rhinometric assessment using acoustic rhinometer

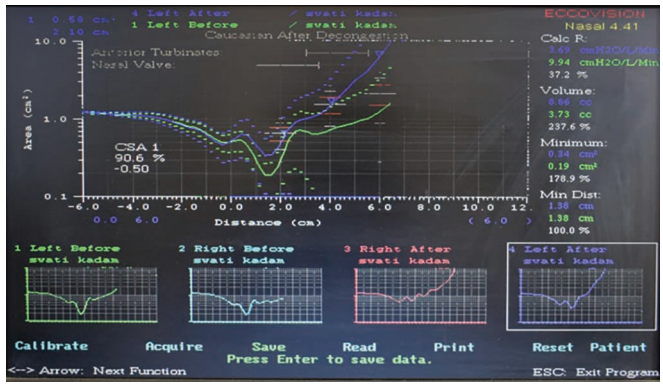

Fig. 2: Graphic representation of nasal volume and nasal area

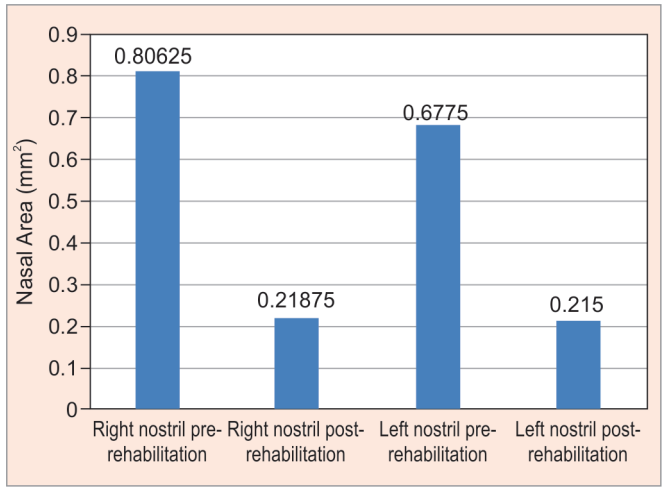

Fig. 3: Comparison of nasal area (right and left nostril) with and without obturator

Results

Eight patients having Aramany's class IV maxillectomy defects with obturator prosthesis were evaluated for CSA and nasal volume using Eccovision Acoustic Rhinometer system. The mean age of our patients was 44.62 ± 8.74 years. Three patients were females (37.5%) and the remaining five were males (62.5%). Comparison of nasal area of right and left nostril, with and without obturator was presented in Figure 3. A comparison of the nasal volume of right and left nostril, with and without obturator was presented in Figure 4. The mean right nasal CSA before rehabilitation was 0.806 ± 0.158 mm^2 and it significantly reduced to 0.218 ± 0.039 mm^2 after the use of an obturator prosthesis ($p < 0.0001$) (Table 1). Similarly, the right nasal volume which was 8.302 ± 1.229 cm^3, significantly improved to 3.281 ± 0.44 cm^3 after rehabilitation with obturator prosthesis ($p < 0.0001$) (Table 2). The average left nasal CSA and nasal volume were compared with and without prosthesis and they too showed a significant improvement from 0.677 ± 0.281 mm^2 to 0.215 ± 0.038 mm^2 and 8.81 ± 0.982 cm to 3.65 ± 0.300 cm^3, respectively ($p < 0.0001$) (Tables 3 and 4).

Discussion

Maxillectomy defects created after surgical resection of the maxilla and the associated structures often require prosthodontic management for rehabilitation of the defect.[7] Obturator prosthesis

is the standardized prosthodontic treatment modality for the rehabilitation of such defects.[8] Aramany has explained the prosthesis design for different types of maxillectomy defects.[9] For standardization of the prosthesis design, patients who fall in the same class of Aramany's classification were selected in the study.

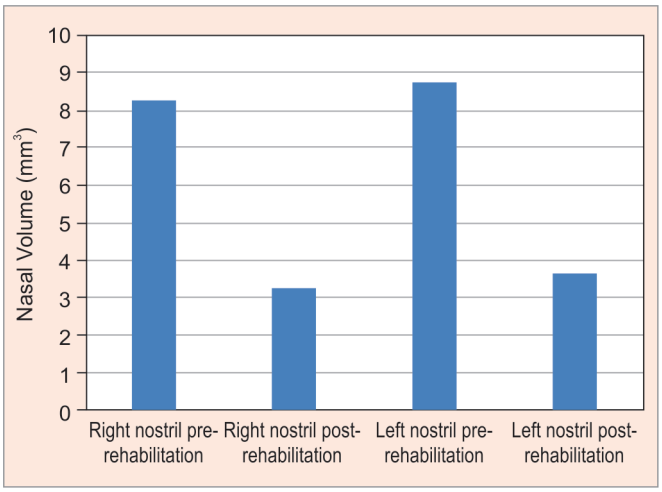

Fig. 4: Comparison of nasal volume (right nostril and left nostril) with and without obturator

The extension of the obturator prosthesis is an important aspect of successful rehabilitation. The restoration of functional anatomy and physiology is a great challenge for the prosthodontist. Restoring the nasal area and volume, which largely depends upon the extension of the bulb of the obturator prosthesis, would help the patient in normal declaration, respiration, and phonation.

Various diagnostic modalities have been used for the assessment of nasal patency. Rhinomanometry based on nasal airflow resistance is the most commonly used method for evaluation of the same.[10,11] Modification to conventional rhinomanometry was introduced by Warren,[11] who showed that values of <0.40 cm^2 are indicative of nasal obstruction. The other modalities include CT and MRI.[4,5] Acoustic rhinometry, a noninvasive method for evaluation of the nasal area and nasal volume, was first introduced after the study conducted by Hilberg et al.[12] The technique is based on the data collected from sound waves reflected by the nasal cavity. The sound waves are introduced into the nasal cavity and reflected waves are analyzed to create a topographical profile of the nasal cavity. The nasal area and nasal volume can be measured at different levels.[13]

Acoustic rhinometry is a specific technique for the determination of nasal patency.[14] It also provides objective measurements of the severity of obstruction.[15] The role of this method is well established in comparing pre and postoperative status of the nasal cavity.[16,17] It provides the additional advantages of being rapid, convenient, and comfortable for the patient.

Table 1: Paired *t*-test paired for means comparing right nostril area postmaxillectomy with and without obturator

	Without obturator	*With obturator*
Mean (mm^2)	0.806	0.218
Variance	0.025	0.001
Observations	8	8
Pearson correlation	0.858	
Hypothesized mean difference	0	
Df	7	
t-stat	13.104	
p (T ≤ *t*) one-tail	1.756	
t critical one-tail	1.894	
p (T ≤ *t*) two-tail	3.513	

Table 2: Paired *t*-test paired for means comparing right nostril volume postmaxillectomy with and without obturator

	Without obturator	*With obturator*
Mean (mm^2)	8.818	3.657
Variance	0.965	0.090
Observations	8	8
Pearson correlation	−0.072	
Hypothesized mean difference	0	
Df	7	
t-stat	13.928	
p (T ≤ *t*) one-tail	1.162	
t critical one-tail	1.894	
p (T ≤ *t*) two-tail	2.325	
t critical two-tail	2.364	

Table 3: Paired *t*-test paired for means comparing left nostril area post-maxillectomy with and without obturator

	Without obturator	*With obturator*
Mean (mm^2)	0.677	0.215
Variance	0.0790	0.001
Observations	8	8
Pearson correlation	0.686	
Hypothesized mean difference	0	
/df	7	
t-stat	5.108	
p (T ≤ *t*) one-tail	0.001	
t Critical one-tail	1.894	
p (T ≤ *t*) two-tail	0.001	
t critical two-tail	2.364	

Table 4: Paired *t*-test paired for means comparing left nostril volume postmaxillectomy with and without obturator

	Without obturator	*With obturator*
Mean (mm^2)	8.302	3.281
Variance	1.510	0.197
Observations	8	8
Pearson correlation	0.531	
Hypothesized mean difference	0	
Df	7	
t-stat	13.371	
p (T ≤ *t*) one-tail	1.533	
t critical one-tail	1.894	
p (T ≤ *t*) two-tail	2.325	
t critical two-tail	2.364	

There are certain disadvantages, which include the incorporation of error due to temperature variations and external noise, which affects the accuracy and sensitivity of the technique. Also, the improper placement of the rhinometer in the nostrils and change in head position can cause errors in the measured values.[15]

The goal of the fabrication of an obturator prosthesis is not only to restore the function of mastication but also to restore the normal function of speech and respiration. The assessment of restoration of normal respiration is an important indicator for the success of the prosthesis. Researchers have given specific values for the nasal area and nasal volume using various methods.[18–20] Few studies have validated the assessment of normal values of nasal area and nasal volume using rhinometry.[21–23] The results of our study were in congruence with the normal values of nasal area (0.5 cm^2) and nasal volume (4.02 cm^3) as given by Gomes et al.[6] However, the study also showed that the hollow bulb portion of the obturator does not completely obturate the whole defect, though the values are closer to the normal, thus validating their design and a definitive mode of rehabilitation of the maxillectomy defects.

Limitations of this study are that the reliability of utilizing Eccovision Acoustic Rhinometer is yet to be proved. Also, further studies with definitely more sample size are required to declare this method as a standard technique for assessment of the extent of the obturator prosthesis.

Conclusion

Restoration of form, function, esthetics, phonetics, and health, along with patient comfort, are the important parameters for assessment of the successful rehabilitation of the maxillectomy defects. The objective evaluation of restoration of normal respiration using rhinometry further confirms the rehabilitation closer to the normal anatomy. Hence, it is recommended that rhinometry can be used as a reliable tool for the assessment of nasal patency in postmaxillectomy patients rehabilitated with obturator prosthesis.

References

1. Omo J, Sede M, Enabulele J. Prosthetic rehabilitation of patients with maxillary defects in a Nigerian tertiary hospital. Ann Med Health Sci Res 2014;4(4):630–633. DOI: 10.4103/2141-9248.139352
2. Bhasin AS, Singh V, Mantri SS. Rehabilitation of patient with acquired maxillary defect, using a closed hollow bulb obturator. Indian J Palliat Care 2011;17(1):70–73. DOI: 10.4103/0973-1075.78453
3. Singh M, Bhushan A, Kumar N, et al. Obturator prosthesis for hemimaxillectomy patients. Natl J Maxillofac Surg 2013;4(1):117–120. DOI: 10.4103/0975-5950.117814
4. Min YG, Jang YJ. Measurements of cross-sectional area of the nasal cavity by acoustic rhinometry and CT scanning. Laryngoscope 1995;105(7 Pt 1):757–759. DOI: 10.1288/00005537-199507000-00014
5. Dastidar P, Numminen J, Heinonen T, et al. Nasal airway volumetric measurement using segmented HRCT images and acoustic rhinometry. Am J of Rhinol 1999;13(2):97–103. DOI: 10.2500/105065899782106706
6. de Oliveira Camargo Gomes A, Sampaio-Teixeira ACM, Trindade SHK, et al. Nasal cavity geometry of healthy adults assessed using acoustic rhinometry. Rev Bras Otorhinolaryngol 2008;74(5):746–754. DOI: 10.1016/S1808-8694(15)31386-0
7. Andrades P, Militsakh O, Hanasono MM, et al. Current strategies in reconstruction of maxillectomy defects. Arch Otolaryngol Head Neck Surg 2011;137(8):806–812. DOI: 10.1001/archoto.2011.132
8. Depprich R, Naujoks C, Lind D, et al. Evaluation of the quality of life of patients with maxillofacial defects after prosthodontic therapy with obturator prostheses. Int J Oral Maxillofac Surg 2011;40(1):71–79. DOI: 10.1016/j.ijom.2010.09.019
9. Aramany MA. Basic principles of obturator design for partially edentulous patients. Part I: classification. J Prosthet Dent 1978;40(5):554–557. DOI: 10.1016/0022-3913(78)90092-6
10. Warren DW, Drake AF. Cleft nose. Form and function. Clin Plast Surg 1993;20(4):769–779. DOI: 10.1016/S0094-1298(20)32383-X
11. Warren DW. A quantitative technique for assessing nasal airway impairment. Am J Orthod 1984;86(4):306–314. DOI: 10.1016/0002-9416(84)90141-6
12. Hilberg O, Jackson AC, Swift DL, et al. Acoustic rhinometry: evaluation of nasal cavity geometry by acoustic reflection. J Appl Physiol 1989;66(1):295–303. DOI: 10.1152/jappl.1989.66.1.295
13. Banari AS, Datana S, Agarwal SS, et al. Evaluation of nasal patency among patients with unilateral cleft lip and palate: cleft versus non-cleft side. Cleft Palate Craniofac J 2021;58(3):340–346. DOI: 10.1177/1055665620948719
14. Hilberg O, Jensen FT, Pedersen OF. Nasal airway geometry: comparison between acoustic reflections and magnetic resonance scanning. J Appl Physiol (1985) 1993;75(6):2811–2819. DOI: 10.1152/jappl.1993.75.6.2811
15. Hilberg O, Pedersen OF. Acoustic rhinometry: recommendations for technical specifications and standard operating procedures. Rhinol Suppl 2000;16:3–17.
16. Lenders H, Pirsig W. Diagnostic value of acoustic rhinometry: patients with allergic and vasomotor rhinitis compared with normal controls. Rhinology 1990;28(1):5–16.
17. Mamikoglu B, Houser S, Akbar I, et al. Acoustic rhinometry and computed tomography scans for the diagnosis of nasal septal deviation, with clinical correlation. Otolaryngol Head Neck Surg 2000;123(1 Pt 1):61–68. DOI: 10.1067/mhn.2000.105255
18. Roithmann R, Cole P, Chapnik J, et al. Acoustic rhinometry in the evaluation of nasal obstruction. Laryngoscope 1995;105(3 Pt 1):275–281. DOI: 10.1288/00005537-199503000-00010
19. Roithmann R, Chapnik J, Zamel N, et al. Acoustic rhinometric assessment of the nasal valve. Am J Rhinol 1997;11(5):379–385. DOI: 10.2500/105065897781286016
20. Krzych-Fałta E, Szczęsnowicz-Dąbrowska P, Samoliński B, et al. The normal ranges of selected acoustic rhinometry parameters depending on age and sex-component of standarization in nasal provocation test. Postepy Dermatol Alergol 2022;39(1):171–181. DOI: 10.5114/ada.2021.105360
21. Kesavanathan J, Swift DL, Bascom R. Nasal pressure-volume relationships determined with acoustic rhinometry. J Appl Physiol (1985) 1995;79(2):547–553. DOI: 10.1152/jappl.1995.79.2.547
22. Corey JP, Gungor A, Nelson R, et al. Normative standards for nasal cross-sectional areas by race as measured by acoustic rhinometry. Otolaryngol Head Neck Surg 1998;119(4):389–393. DOI: 10.1016/S0194-5998(98)70085-3
23. Cakmak O, Coşkun M, Celik H, et al. Value of acoustic rhinometry for measuring nasal valve area. Laryngoscope 2003;113(2):295–302. DOI: 10.1097/00005537-200302000-00018