

Assessment and Comparison of the Condylar Guidance by Protrusive Interocclusal Records and Panoramic Radiographic Imaging in Edentulous and Dentulous Individuals

¹Bisma Amin, ²GP Surendra Kumar, ³Bharat Raj, ⁴Shilpa Shetty, ⁵Archana Shetty, ⁶Arjun Mithra

ABSTRACT

Aim: To compare the condylar guidance angle obtained by extraoral Gothic arch tracing, protrusive interocclusal records (IORs), and orthopantomogram (OPG) in completely edentulous and dentulous subjects.

Materials and methods: A total of 30 edentulous and 30 dentulous subjects were selected. Conventional steps in the fabrication of complete denture with balanced occlusion were carried out. Extraoral Gothic arch tracing records were obtained from each subject. Protrusive IORs were used to program the Hanau Wide-View semiadjustable articulator, to obtain the sagittal condylar guidance angle. The sagittal condylar guidance was determined in 60 subjects by protrusive IORs and facebow transfer. The sagittal outline of the articular eminence and glenoid fossa was traced in panoramic radiographs. The sagittal condylar path inclination was constructed by joining the heights of curvature in the glenoid fossa and the corresponding articular eminence. This was then related to the constructed Frankfurt horizontal plane to determine the radiographic angle of sagittal condylar guidance.

Results: There was statistically significant difference between the sagittal condylar guidance values obtained using extraoral Gothic arch tracing and OPG method ($p = 0.0237$) in edentulous subjects. Statistically significant values were obtained using protrusive records and OPG method ($p = 0.0237$) in dentulous subjects.

Conclusion: The use of OPG to set condylar guidance on the articulator should be taken into consideration for both dentulous and edentulous subjects.

Clinical significance: In clinical practice, the use of IORs following Gothic arch tracing for the programming of semiadjustable articulator may be associated with manual errors. To minimize the errors and to obtain more accurate sagittal condylar guidance values, the use of OPG along with IORs should be considered for programming of the semiadjustable articulator.

Keywords: Articular eminence, Gothic arch tracing, Panoramic radiographs, Protrusive interocclusal registration, Sagittal condylar guidance.

How to cite this article: Amin B, Kumar GPS, Raj B, Shetty S, Shetty A, Mithra A. Assessment and Comparison of the Condylar Guidance by Protrusive Interocclusal Records and Panoramic Radiographic Imaging in Edentulous and Dentulous Individuals. *Int J Prosthodont Restor Dent* 2018;8(1):10-16.

Source of support: Nil

Conflict of interest: None

INTRODUCTION

For a successful treatment outcome, a prosthesis has to be in harmony with the patient's stomatognathic system. This is possible when the articulator is programmed according to the patient's condylar guidance to simulate the mandibular movements, hence, developing an occlusion in harmony with health and function of the stomatognathic system.¹

The most important consideration in the oral rehabilitation of any patient is the inclination of the condylar path, which is the path traversed by the condyle in relation to the articular eminence when the mandible is moved either protrusively or laterally from centric relation. Condylar guidance is the mechanical form located in the upper posterior region of an articulator that controls movement of its mobile member. The purpose of protrusive jaw relation is to set the condylar elements of the articulator so that they will reproduce inclinations, which are similar or comparable to that of the patient's temporomandibular articulation.²

There are various intraoral and extraoral methods, which have been used to register the path of the condyle and adjust the articulator. Interocclusal records and Gothic arch tracings are commonly used methods for clinical practice.

Other than clinical methods, literature indicates the use of radiographic techniques as they involve stable bony landmarks and can be standardized. Various radiographic techniques used are lateral cephalograms, OPGs, and tomographs. Orthopantomogram is the routinely obtained diagnostic aid with least radiation exposure.¹ Thus, the study was designed to compare the subcallosal gyros (SCG) angle (on left and right sides) obtained by IORs to the SCG angle measured on OPG in edentulous and dentulous subjects.

¹Postgraduate Student, ²Professor, ^{3,5,6}Reader, ⁴Professor and Head

¹⁻⁶Department of Prosthodontics, Vokkaligara Sangha Dental College & Hospital, Bengaluru, Karnataka, India

Corresponding Author: Bisma Amin, Postgraduate Student Department of Prosthodontics, Vokkaligara Sangha Dental College & Hospital, Bengaluru, Karnataka, India, e-mail: bismaamin547@gmail.com

MATERIALS AND METHODS

Source of Data

A total of 30 completely edentulous subjects and 30 fully dentate subjects were selected among those reporting to the Outpatient Department, Department of Prosthodontics, VS Dental College and Hospital, V.V. Puram, Bengaluru, Karnataka, India.

Methods of Collection of Data

Condylar guidance value was obtained from the radiographs and protrusive IORs.

Inclusion Criteria

For dentulous subjects

- Subjects in the age group of 40 to 60 years
- Near ideal occlusion of the remaining teeth

For edentulous subjects

- Subjects in the age group of 40 to 60 years
- Absence of any pathology in temporomandibular joint (TMJ)

Exclusion Criteria

- Subjects with TMJ disease and muscle disorder
- Malocclusion (in case of dentulous subjects)
- Subjects with craniofacial anomalies

STUDY METHOD

The study was approved by the Institutional Review Board and informed consent was obtained from the patients.

For Edentulous Subjects

Protrusive IORs

For each of the 30 edentulous subjects requiring complete denture, conventional steps in the fabrication of complete denture with balanced occlusion were carried out. Jaw relation was recorded and facebow (HANAUTM Spring Bow, Whip Mix Corporation, USA) transfer was done to transfer the relation onto a semiadjustable articulator (HANAUTM Wide-View Articulator). After the transfer, centric relation was recorded and the maxillary cast was secured using plaster and the mandibular cast was mounted using the centric relation record.

A set of Hight extraoral tracers were attached to the occlusal rims (Fig. 1A). The subjects were trained to give Gothic arch tracing, after which, centric and protrusive records (6 mm from centric) were made with plaster for each subject (Fig. 1B). The protrusive record was used to program the articulator. The centric locks and the

horizontal inclination of the condylar guidance on the articulator were loosened. The incisal pin was raised to remove the possibility of mechanical interference with the incisal guide. The protrusive interocclusal relation record was seated onto the lower occlusal rim. The upper member was carefully guided into protrusion, lightly engaging into the imprint of the protrusive relation record. The right and left condylar guidance were rotated back and forth to accurately seat the upper and lower rims into the protrusive relation record. Making sure that the occlusal rims seated without rocking in or deforming the record, the thumbnuts for horizontal inclination were tightened. The protrusive relation record was then removed. Thus, horizontal condylar inclinations (HCIs) on both sides of the articulator were set. The right and left SCG values on articulator were tabulated.

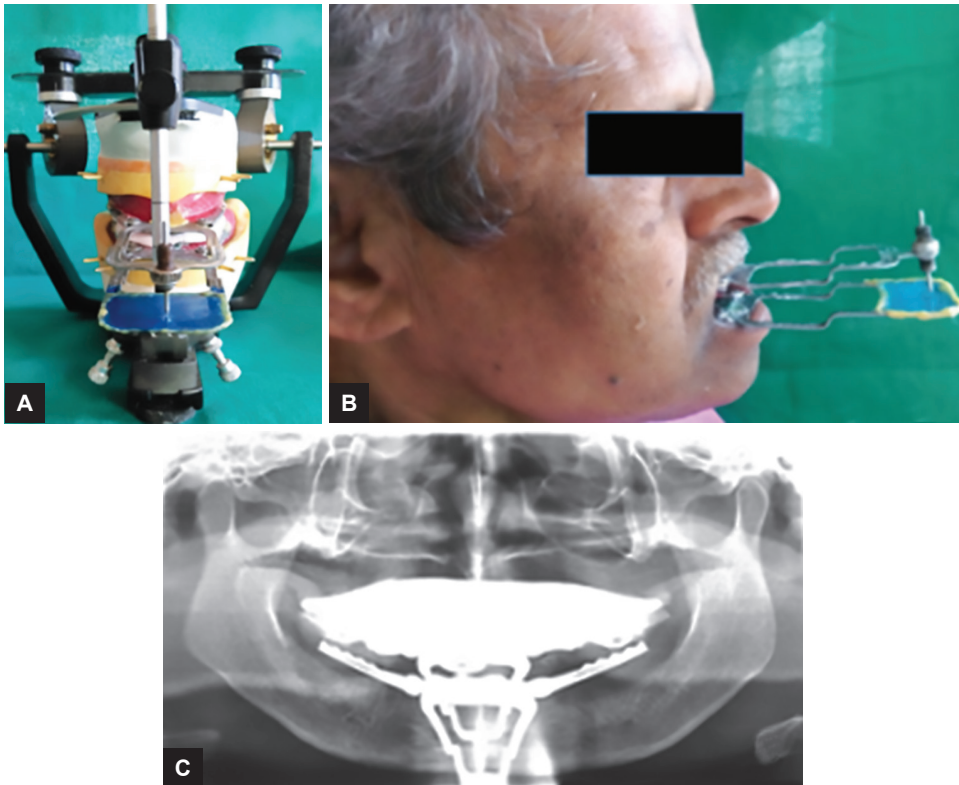
Panoramic Radiography

The radiographic procedures were carried out in Department of Oral Radiology, VS Dental College and Hospital. The radiographic unit comes with a beam of light aligned along the anatomic planes, and a cephalostat was used to align the head in the same position for all patients. All radiographs were made by a single operator in the same radiographic unit (orthophos XG) with exposure factors of 64 kVp and 8 mA for 14.5 seconds. The images were printed to 100% scale on Fujifilm in a Fujifilm (dry pix prima) printer. An OPG of the jaws with the rims and the tracers attached to hold the mandible in the protruded position was obtained for each subject (Fig. 1C). The sagittal outlines of the left and right articular eminence and glenoid fossae were traced on a transparent acetate tracing sheet. The left and right "orbitale" (lowest point on the margin of the orbit) and "porion" (highest point on the margin of the auditory meatus) were identified and the Frankfurt horizontal plane was constructed by joining the two landmarks on each side. The most superior point on the articular eminence and the most inferior point on the articular tubercle were identified and a second line to represent the mean condylar path inclination was constructed by joining the two points. The angle formed by the intersection of the two lines was determined to represent the angle of sagittal condylar inclination (Fig. 2). The values obtained were tabulated.

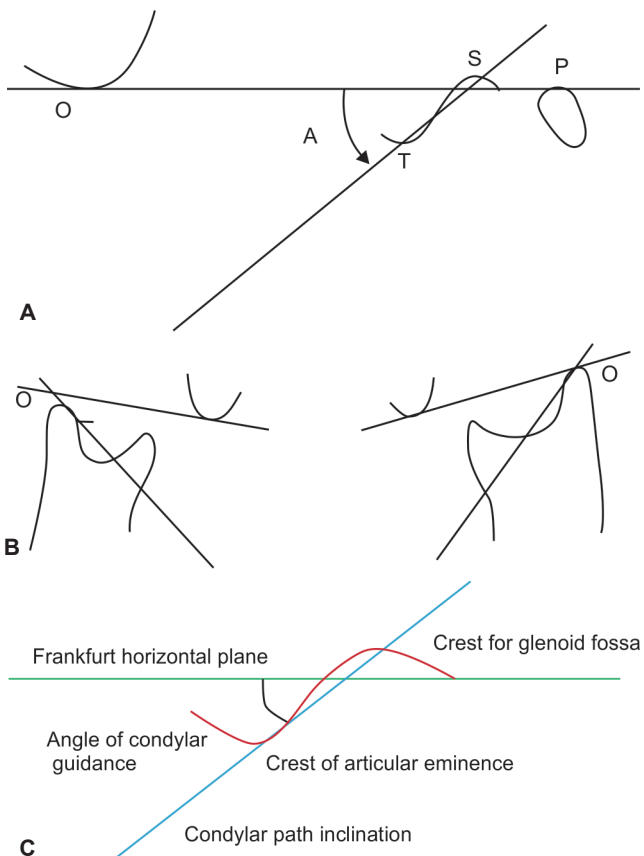
For Dentulous Subjects

Protrusive IORs

For each of the 30 dentulous subjects, primary impression of the arches was made using an irreversible hydrocolloid impression material and cast was poured immediately



Figs 1A to C: (A) Tracers attached to maxillary and mandibular cast; (B) Gothic arch tracing with 6 mm protrusion; (C) obtaining SCG values using OPG



Figs 2A to C: (A) Tracing of OPG; (B) tracing of the line SI joining height of superior curvature and interior curvature. Occlusal plane is Frankfurt horizontal plane. A is the angle made by the intersection of the mean curvature line and horizontal reference line; (C) line diagram of the panoramic tracing of the angle of sagittal condylar guidance

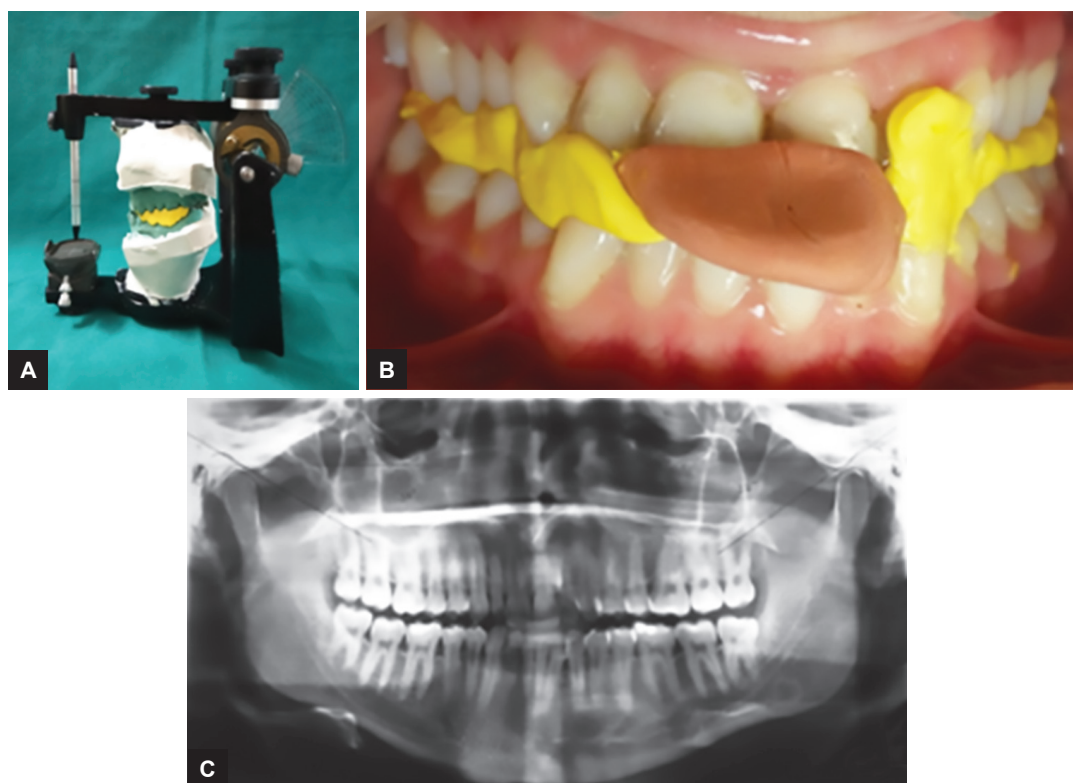
using type III dental stone. Using facebow transfer, the cast was mounted on to the semiadjustable articulator. Mandibular cast was mounted using the subject's maximum intercuspation record.

To fabricate a jig at 6 mm protrusion, the mandibular buccal groove of first molar on the mounted cast was taken as a standardized starting point. Using a scale and a divider, a point was marked 6 mm ahead on the opposing maxillary second premolar of the mounted cast. The upper member of the articulator was protruded until the mandibular groove and the marked point on maxillary cast coincided, after which the jig was fabricated using impression compound, which extended across maxillary anterior teeth.

After the preparation of the jig, bite registration media (Jet bite Coltene/Whaledent, New York) was injected over the posterior teeth with the jig in place over the anterior teeth on the articulator. The articulator was programmed and the horizontal condylar guidance (HCG) values were obtained from the transfer (Fig. 3A). These values were noted for each subject.

Panoramic Radiography

Same steps were carried out to record the angles on the OPG as mentioned for the edentulous subjects and the values obtained were tabulated (Figs 3B and C). Thereafter, a comparison was made on the values obtained by both the methods.



Figs 3A to C: (A) Obtaining HCG values using protrusive record at 6 mm; (B) bite registration and jig in patient's mouth; (C) obtaining HCG values using OPG

Statistical Analysis

Unpaired t-test was used for comparison between the different study groups. Data obtained were subjected to statistical analysis using Statistical Package for the Social Sciences version 18 software.

RESULTS

The present study was done to determine the condylar guidance values in edentulous and dentulous individuals using radiograph (OPG) and protrusive IOR made using arrow point tracing and to compare the

condylar guidance values obtained by the two different methods.

In edentulous subjects, the mean condylar guidance value using OPG was found to be 29.10 and using IOR it was found to be 24.20. On comparison of condylar guidance values obtained using both the methods, the results were statistically significant ($p = 0.0237$) (Table 1).

In dentulous subjects, the mean condylar guidance value using OPG was found to be 35.53 and using IOR it was found to be 30.83. On comparison of condylar guidance values obtained using both the methods, the results were statistically significant ($p = 0.0028$) (Table 2).

Table 1: Comparison of condylar guidance values obtained using OPG and IOR in edentulous subjects

Group	Number of subjects (n)	Condylar guidance values					
		Minimum (degrees)	Maximum (degrees)	Mean	Standard deviation	t-value	p-value
OPG	30	10	46	29.10	9.135	2.323	0.0237*
IOR	30	14	45	24.20	7.066		

Unpaired t-test; $p < 0.05$; the difference between mean condylar guidance values obtained using OPG and IOR in edentulous subjects is statistically significant ($p = 0.0237^*$)

Table 2: Comparison of condylar guidance values obtained using OPG and IOR in dentulous subjects

Group	Number of subjects (n)	Condylar guidance values					
		Minimum (degrees)	Maximum (degrees)	Mean	Standard deviation	t-value	p-value
OPG	30	17	44	35.53	6.248	3.121	0.0028*
IOR	30	19	42	30.83	5.384		

Unpaired t-test; $p < 0.05$; the difference between mean condylar guidance values obtained using OPG and IOR in dentulous subjects is statistically significant ($p = 0.0028^*$)

DISCUSSION

Condylar guidance is defined as the mandibular guidance generated by the condyle and articular disk traversing the contour of the articular eminence.³ If condylar guidance is not recorded accurately, it will lead to occlusal interference during mandibular movements. The condylar guidance in semiadjustable articulators is set either by individual protrusive or lateral interocclusal registrations. The purpose of the protrusive jaw relation is to set the condylar elements of the articulator so they will reproduce inclinations, which are exact or nearer to the patients temporomandibular articulation. The methods used to record condylar guidance clinically are either extraoral or intraoral methods.⁴

Most commonly used intraoral methods are interocclusal protrusive wax records, Lucia jig, leaf gauge, and intraoral tracers. Intraoral or positional wax method, graphic recordings, and functional recordings can be used to record centric and eccentric relations.⁵ According to Isberg et al,⁶ a high degree of correlation exists between the protrusive condylar path and the steepness of articular eminence, which may be attributed to the active role played by the soft tissues during condylar movements. Gilboa et al⁷ reported a high degree of correlation between articular morphology and panoramic images and suggested that the inclination of the articular eminence in a panoramic image may be of value in setting the condylar guidance in semiadjustable articulators, which supports the present study. The correlation between mean sagittal readings of the Hanau Wide-View articulator and radiographic (OPG) readings could be possibly due to the anatomic representation of the articulator design in close approximation with the human TMJs.

Articulators are mechanical devices, which can simulate the mandibular movements, and are used in diagnostic and therapeutic purpose. Banasr et al⁸ mentioned in a study that the average values of condylar guidance range from 22° to 65°. Gross et al⁹ found significant difference between three semiadjustable articulators (Denar Mark II, Hanau 158, Whip Mix) used for comparative study of condylar settings. Whip Mix consistently gave the highest angulations and Hanau 158 the lowest.

Tannamala et al³ conducted a study on correlation between protrusive IOR and panoramic radiographic image in which it was observed that the radiographic values were on average 4° greater than the value obtained by protrusive IOR method. The difference in mean condylar guidance angle between the right and left side by both the methods was not statistically significant.

Horizontal condylar guidance changes with amount of protrusion, so it is important to keep the distance of protrusion the same. Posselt et al¹⁰ reported that

correlation exists between degrees of protrusion that can influence the setting of condylar readings. In the present study the amount of protrusion was kept same for all the subjects (6 mm protrusion) and the same protrusive records were used for programming the articulator.

The result is in accordance with the studies done by Shillingburg et al¹¹ and Rosensteil et al¹² who stated that the nonarcon design condylar inclination of the mechanical fossae changes in relation to the maxillary occlusion plane as the articulator is opened and can lead to errors when a protrusive record of certain thickness is being used to program the articulator. They reported that with 3 to 5 mm thickness of IOR, there would be a difference of 8° between where the articulator settings are adjusted and a closed position where the articulator is used.

Panoramic radiography is widely used for diagnosis in dentistry. Gilboa et al,⁷ through their study on 25 dry human skulls, determined that the radiographic outline of articular fossa and articular eminence in a panoramic radiographic image is an accurate representation of equivalent outlines in the skull and can be of value in determining condylar guidance angles. A panoramic radiograph provides the clinician with a comprehensive view of the entire maxillomandibular region, producing an image of both dental arches on a single film. Image magnification and distortion limit accuracy in panoramic radiography. The distortions result from the horizontal movement of the film and X-ray source.²

The OPG image reproduces the actual form and angles of the osseous structure of the TMJ. The present study traced the articular eminence inclination in the radiographic image from the most superior to the most inferior points of curvature and this may be different from guiding inclination of protrusion recorded by IOR.

There are some limitations of the radiographic method concerning panoramic distortion, head and reference plane orientation, and difficulty in distinguishing the articular eminence outline from the zygomatic arch. The positions of these two lines relative to each other may vary if there is a change in beam direction due to positioning errors. This may be different from the guiding inclination with approximately 4 to 6 mm of protrusion, which is the clinically significant range of protrusion and condylar guidance. Despite these drawbacks, the panoramic radiograph is extremely useful for comparison between right and left sides since it shows both the TMJs with relatively same magnification errors ($\times 1.2$).⁶

The patients head positioning is important in panoramic radiography because poor positioning techniques may result in structures lying outside the focal trough, causing images to be blurred and distorted.¹³ This was in accordance to a study done by Rohlin and Akerblom.¹⁴ McDavid et al¹⁵ stated that distortion can create images

that are either too wide or too narrow, depending on whether the structures are on the film or source side of the focal trough.

In this study, the OPG machine used was equipped with a cephalostat, which helped in accurate placement of the patient's head. The articular eminence inclination in the OPG image was traced from the most superior to the most inferior points of curvature and was recorded as SCG angle.

Comparative studies using IOR materials to record HCI have shown that selection of the material is an important factor to be considered. Most of these IOR materials were shown having varying degrees of reproducibility of condylar inclinations when used along with different semiadjustable articulators.⁶

Vergos and Tripodakis¹⁶ evaluated four recording materials (polyether, polyvinyl siloxane, acrylic resin, and wax) for their ability to accurately record, maintain, and reproduce the vertical interocclusal relationship using metallic apparatus, representing the opposing arches. It was observed that the IOR materials produced small vertical discrepancies ranging from 24 to 74 μm . The lowest discrepancy was displayed by polyvinyl siloxane and polyether, and the greatest was displayed by wax.

On comparison of condylar guidance values obtained using OPG and IOR in edentulous subjects, it was observed that value obtained from OPG was greater by 4.9° than that obtained from IOR, which was statistically significant. This is in accordance with the findings of the study done by Kumari et al¹ who also found that there is statistically significant difference between the sagittal condylar guidance values obtained between right and left sides with extraoral Gothic arch tracing and orthopantomographic method.

On comparison of condylar guidance values obtained using OPG and IOR in dentulous subjects, it was observed that value obtained from OPG was greater by 4.7° than that obtained from IOR, which was statistically significant. A study conducted by Prasad et al² also showed that the different values obtained by the two methods were highly significant.

In this study, Hanau Wide-View semiadjustable articulator was used to receive the intraoral records obtained from extraoral Gothic arch tracing. Fixed intercondylar distances and the straight condylar pathways limited the capability of the articulator to accurately simulate the TMJs and their movements, leading to errors in horizontal and frontal plane. Arbitrary hinge axis is being used to transfer the facebow record to the articulator. This may be the reason for the difference in radiographic and clinical techniques. Orthopantomogram obtained for this study was done with a digital X-ray machine to record individual sagittal condylar guidance values,

which was considered as a standard for comparison with the articulator. The panoramic radiographic image of the sagittal outline of the articular eminence and glenoid fossa was clearly identified in 60 subjects. A panoramic radiographic image in the temporal region shows the outer radiopaque line depicting the articular eminence and inner radiopaque line depicting the inferior border of the zygomatic arch. These lines often intersect and can be confusing due to significant limitations of panoramic radiographs imputable to distortions inherent in the panoramic system and errors in patient positioning. The mean curvature of the articular eminence in the panoramic radiographic image was recorded as condylar guidance angle.³

Thus, the result of the present study concluded that the panoramic radiographic tracings of the sagittal condylar path guidance may be made relative to the Frankfurt horizontal reference plane and the resulting condylar guidance angles may be used to set the condylar guide setting of semiadjustable articulators both for dentulous and for edentulous patients. At the same time, based on the results of this study, it is not justified to omit the use of radiographic techniques.

CONCLUSION

A study was conducted in which

- The mean condylar guidance value using OPG was found to be higher than in IORs in edentulous subjects. On comparison of condylar guidance values obtained using both the methods, the results were statistically significant ($p = 0.0237$) and
- The mean condylar guidance value using OPG was found to be higher than when using IORs in dentulous subjects. On comparison of condylar guidance values obtained using both the methods, the results were statistically significant ($p = 0.0028$).

It was concluded that a difference was found between the condylar guidance values obtained by the OPG and the most commonly used extraoral Gothic arch tracing method in edentulous patients. Hence, the use of OPG to set the condylar guidance on the articulator should be taken into consideration.

REFERENCES

1. Kumari VV, Anehosur GV, Meshramkar R, Nadiger RK, Lekha K. An *in vivo* study to compare and correlate sagittal condylar guidance obtained by radiographic and extraoral gothic arch tracing method in edentulous patients. *Eur J Prosthodont* 2016 May;4(1):12-16.
2. Prasad DK, Shah N, Hegde C. A clinicoradiographic analysis of sagittal condylar guidance determined by protrusive interocclusal registration and panoramic radiographic images in humans. *Contemp Clin Dent* 2012 Oct;3(4):383-387.

3. Tannamala PK, Pulagam M, Pottem SR, Swapna B. Condylar guidance: correlation between protrusive interocclusal record and panoramic radiographic image: a pilot study. *J Prosthodont* 2012 Apr;21(3):181-184.
4. Hickey JC, Zarb GA, Bolender CL. Boucher's prosthodontic treatment for edentulous patients. 9th ed. St. Louis (MO): CV Mosby; 1985. p. 415.
5. Shah RJ, Agarwal P, Negi P. A comparative analysis of sagittal condylar guidance determined by two articulator systems and orthopantomographs (OPG) in completely edentulous patients. *Indian J Dent Sci* 2013 Oct;5(4):72-76.
6. Isberg A, Westesson PL. Steepness of articular eminence and movement of the condyle and disk in asymptomatic temporomandibular joints. *Oral Surg Oral Med Oral Pathol Oral Radiol Endod* 1998 Aug;86(2):152-157.
7. Gilboa I, Cardash HS, Kaffe I, Gross MD. Condylar guidance: correlation between articular morphology and panoramic radiographic images in dry human skulls. *J Prosthet Dent* 2008 Jun;99(6):477-482.
8. Banasr FH, Shinawi LA, Soliman IS, Al-Rafah EM, Abdelsalam Z. A comparative evaluation to measure the sagittal condylar guidance values between the semiadjustable articulators and radiographic images. *Smile Dent J* 2015 Sep;10(3):12-18.
9. Gross M, Nemcovsky C, Friedlander LD. Comparative study of condylar settings of three semiadjustable articulators. *Int J Prosthodont* 1990 Mar-Apr;3(2):135-141.
10. Posselt U, Skytting B. Registration of the condyle path inclination: variation using the Gysi technique. *J Prosthet Dent* 1960 Mar-Apr;10(2):243-247.
11. Shillenburg HT, Hobo S, Whitsett LD, Jacobi R, Brackett SE. Fundamentals of fixed prosthodontics. 3rd ed. Chicago, IL: Quintessence Publishing Co; 1997. p. 42-81.
12. Rosensteil SF, Land MF, Fujimoto J. Contemporary fixed prosthodontics. 4th ed. St. Louis, MO: Mosby; 2006. p. 71-84.
13. Stramotas S, Geenty JP, Petocz P, Darendeliler MA. Accuracy of linear and angular measurements on panoramic radiographs taken at various positions *in vitro*. *Eur J Orthod* 2002 Feb;24(1):43-52.
14. Rohlin M, Akerblom A. Individual periapical radiography determined by clinical and panoramic examination. *Dentomaxillofac Radiol* 1992 Aug;21(3):135-141.
15. McDavid WD, Welander U, Brent Dove S, Tronje G. Digital imaging in rotational panoramic radiography. *Dentomaxillofac Radiol* 1995 May;24(2):68-75.
16. Vergos V, Tripodakis A. Evaluation of vertical accuracy of interocclusal records. *Int J Prosthodont* 2003 Jul-Aug;16(4): 365-368.