

# Analysis of the Esthetic Components of Smile in a Section of North Indian Population

<sup>1</sup>Amrita Grover, <sup>2</sup>Pankaj Dhawan, <sup>3</sup>Piyush Tandan, <sup>4</sup>Pankaj Madhukar

## ABSTRACT

**Aim:** To evaluate the existence of different esthetic smile criteria in a section of North Indian population.

**Materials and methods:** A total of 100 students from Manav Rachna International University were selected based on the inclusion criteria. Two photographs were taken (smiling face and smile) using Digital Single Lens Reflex camera. The statistical analyses used were descriptive statistical tests and Spearman correlation after the images were analyzed using Digimizer image analysis software for different esthetic smile criteria.

**Results:** The coincidence of the facial midline with the arch midline occurred in more than half of the students. Most of the subjects presented parallelism between the incisal plane and the interpupillary line. Mostly parallel or straight smiles were also most commonly observed and the gingival display and the amount of gingival display were relatively less observed.

**Conclusion:** There exists a relationship between facial midline, interpupillary line, smile arc, gingival display, and facial esthetics.

**Clinical significance:** This article describes the existence of different esthetic smile criteria in enhancing the facial esthetics for a pleasing smile.

**Keywords:** Dental esthetics, Facial midline, Gingival display, Interpupillary line, Smile analysis, Smile arc.

**How to cite this article:** Grover A, Dhawan P, Tandan P, Madhukar P. Analysis of the Esthetic Components of Smile in a Section of North Indian Population. *Int J Prosthodont Restor Dent* 2017;7(2):43-47.

**Source of support:** Nil

**Conflict of interest:** None

## INTRODUCTION

The smile constitutes an important component in the presentation of a human being favoring his or her social acceptance. Good appearance is not considered a vanity sign, but literally a need today, and the dentistry has a fundamental role in obtaining it, since the face is the most exposed area of the body and the mouth a prominent feature.<sup>1</sup>

The esthetic value of a cosmetic restoration may be affected by factors contributing to the composition of a pleasing smile, such as amount of gingival display, midline position, gingival architecture, clinical crown dimensions, and tooth position.<sup>2</sup> This emphasized the need for an interdisciplinary approach to evaluate, diagnose, and resolve esthetic problems.<sup>3</sup> Esthetics is the branch of philosophy dealing with beauty.<sup>4</sup>

Anatomic measurements aid in the planning of prosthetic, orthodontic, or restorative treatment, with the objective of obtaining satisfactory esthetics, and one of these measurements includes the parallelism and distance between the pupils and incisal edges of the maxillary central incisors.<sup>5</sup> The second parameter being the facial midline is usually the starting point of the esthetic treatment plan.<sup>6,7</sup> The third parameter, i.e., the smile arc is defined as the relationship between the curvature of the incisal edges of the maxillary anterior teeth and the curvature of the upper border of the lower lip. The esthetics of the smile are affected by the upper lip position, the upper lip curvature, the parallelism of the anterior incisal curve with the lower lip, the relationship between the maxillary anterior teeth and the lower lip, and the number of teeth displayed in the smile.<sup>8</sup> The fourth parameter being the gingival display is also very important for the harmony and symmetry of an esthetic smile among various other components. All of these components together will result in an esthetically pleasing smile.<sup>9</sup> The purpose of the study was to assess whether the need of these parameters helps to aid in the esthetic reconstruction of the smile, considering the buccal and facial components as factors for esthetics.

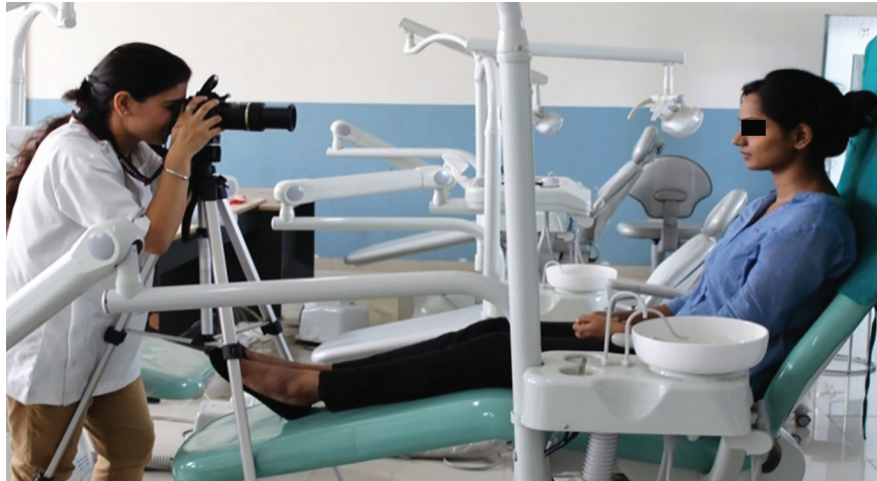## MATERIALS AND METHODS

In this study, a total of 100 subjects of North Indian origin with age ranging from 18 to 25 years studying at Manav Rachna International University were randomly selected. Dentulous subjects with age ranging from 18 to 25 years, with no missing maxillary and mandibular anterior teeth, complete dentate arch with clinical presence or absence of third molars, and subjects with presence of natural maxillary anterior teeth in good alignment were selected in order to meet the inclusion criteria of this project. The exclusion criteria included subjects who had undergone any restoration by a complete veneer crown, partial veneer

<sup>1</sup>Postgraduate Student, <sup>2</sup>Head, <sup>3</sup>Associate Professor, <sup>4</sup>Professor

<sup>1-4</sup>Department of Prosthodontics and Crown and Bridge and Implants, Manav Rachna Dental College, Faridabad, Haryana India

**Corresponding Author:** Amrita Grover, Postgraduate Student Department of Prosthodontics and Crown and Bridge and Implants Manav Rachna Dental College, Faridabad, Haryana, India, Phone: +919899299198, e-mail: amritagrover28@gmail.com

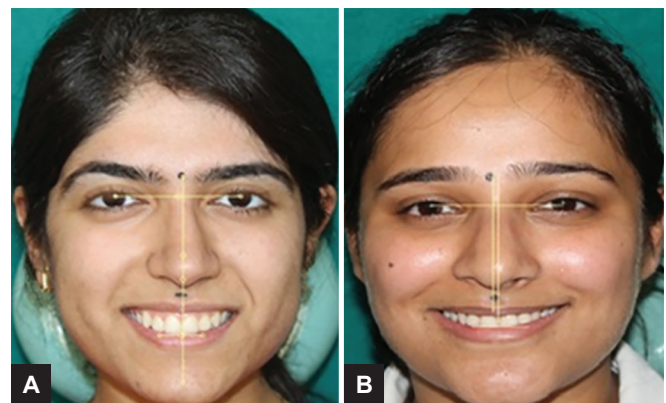


**Fig. 1:** Standardized procedure to obtain lateral view of the full face

crown, partial veneer crown, and crown buildup on the anterior maxillary natural teeth; subjects with absence of orthodontic appliance in the superior anterior teeth and absence of any previous orthodontic treatment; subjects with anterior teeth fractures; subjects with incisal wear of maxillary anterior teeth; and subjects with absence of any previous orthodontic treatment. A participant informed consent form was provided in both Hindi and English languages. A standardized photographic procedure was used to obtain images of the face and maxillary central incisors and was as follows: Each subject was made to sit upright on a chair with the occlusal plane of the maxillary teeth parallel to the floor. Two standardized photographs were taken for each subject: Portrait (social smile) and smile photograph (social smile).<sup>4</sup> For each photograph, standardized distances (portrait: 100 cm, smile photograph 12 cm) were used (from the tip of the subjects' nose to the center of the camera lens). A fixed focus of 1:1 was used for each subject, with the electric field 100 mm  $f/2.8$  macroultrasonic focus motor lens. The height of the Canon electric optical system (EOS) 1100D Digital Single Lens Reflex camera mounted on a tripod (Traveler Mini Pro Tripod For Canon EOS 1100D) was adjusted individually according to the position of the subjects' face and the teeth. The images were then transferred in Digimizer<sup>®</sup> Image Analyzer software version 4.6.0 (Fig. 1).

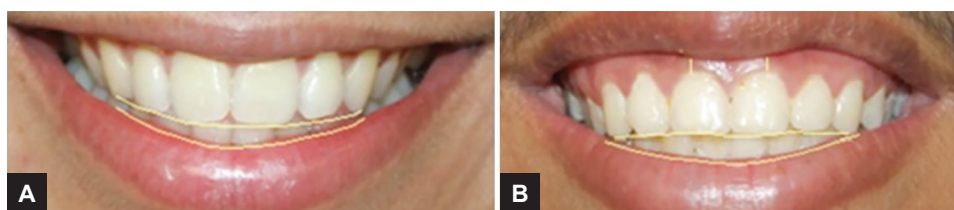In the Digimizer software, the full face photograph was assessed first and then the smile photograph was assessed.

- The first objective was to analyze the parallelism of the incisal plane with the interpupillary line. According to the inclination of the lines, the subjects were classified into two groups, i.e., subjects that present parallelism between the incisal plane line with the interpupillary line and subjects who did not present parallelism between the incisal plane with the interpupillary line lines.

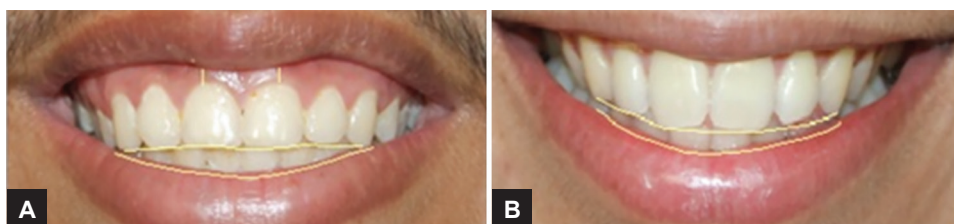

**Figs 2A and B:** (A) Subject with dental midline coinciding with the facial midline; and (B) Subject with dental and facial midline deviation

- The second objective was to analyze and evaluate the presence of a discrepancy between the dental and facial midlines. In this objective, the amount of deviation between the two lines was also measured and evaluated in the Digimizer software in millimeters. According to the inclination of the lines, the subjects were classified into two groups, i.e., subjects who have dental midline that will coincide with the facial midline and subjects having a dental midline that does not coincide with the facial midline deviation (Fig. 2).
- The third and fourth objectives were analyzed by assessing the smile photograph of the subjects. The third objective was the analysis of the parallelism of the maxillary anterior incisal curve with the lower lip. The smile arc was classified as parallel smile arc when the two lines were parallel to each other. Straight smile arc was when the incisal edges of the maxillary anterior teeth were in a straight line. Reverse smile arc meant that the line drawn connecting the incisal edges of the maxillary anterior teeth curved in reverse to the line drawn through the upper border of the lower lip (Fig. 3).



**Figs 3A and B:** (A) Subject showing parallel smile arc; and (B) Subject showing straight smile arc



**Figs 4A and B:** (A) Subject showing gingival display; and (B) Subject showing no gingival display

- In the fourth objective, the visibility of the gingiva in the social (posed) smile was noted. The analyses were done in the Digimizer software by evaluating the gingiva visibility between the zenith of the gingiva of maxillary central incisors and the inferior border of the maxillary lip. The gingival display was measured as group I: Gingival display present and group II: Gingival display absent (Fig. 4).

In the current study, an attempt has been made to increase the accuracy of the methodology by employing a software known as Digimizer image analysis software<sup>®</sup> MedCalc software. Digimizer is a free easy-to-use and flexible image analysis software package that allows precise manual measurements as well as automatic object detection with measurements of object characteristics. Pictures may be photographs, X-rays, micrographs, etc.<sup>8</sup> Finally, the data obtained were arranged systematically and the collected information was transferred onto a master chart which was prepared in Microsoft Excel (2010) with the values obtained for various parameters. The following methods of statistical analysis have been used in this study, i.e., Excel and Statistical Package for the Social Sciences (SPSS Inc, Chicago, version 21.0) software packages were used for data entry and analysis. Statistical methods employed in the present study were descriptive statistical tests and Spearman correlation.

## RESULTS

The data obtained were arranged systematically and the collected information was transferred onto a master

chart which was prepared in Microsoft Excel (2010) with the values obtained for various parameters. As per this study, 83% subjects displayed parallelism of the incisal plane with interpupillary line, 79% subjects had parallelism of the maxillary anterior incisal curve with lower lip, 16% subjects showed gingival display, and 66% subjects had a coincidence between the midline of the face with the midline of the dental arch. Summarized data are presented in Table 1. The results echoed that the factors, such as interpupillary line, midline of the face, smile arc, and gingival display, do affect the smile enhancement, as it helps in basic symmetry and pleasing view, which can be incorporated in the clinical cases on a routine basis.

## DISCUSSION

Smile attractiveness and facial attractiveness appear strongly connected to each other. The fact is that in social interaction, one's attention is mainly directed toward the mouth and eyes of the speaker's face.<sup>10</sup> The essentials of an esthetically pleasing smile involve the relationships between the three primary components: The teeth, the lip framework, and the gingival scaffold.<sup>11</sup> It has been noted that most young adults are more concerned about their appearance of their anterior teeth than their occlusion.<sup>4</sup> Ackerman et al<sup>12</sup> proposed a method to digitally measure the smile characteristics of the dental patients. Specifically, when the "posed smile" is measured; by definition, the posed smile is voluntary and not elicited by an emotion. It can be a learned greeting or a signal of appeasement in an

**Table 1:** Descriptive statistics of study sample

|   | Total no. of cases | Present | Absent |
|---|--------------------|---------|--------|
| Parallelism of the incisal plane with the interpupillary line                   | 100                | 83%     | 17%    |
| Parallelism of the maxillary anterior incisal curve with the lower lip          | 100                | 79%     | 21%    |
| Gingival display during smiling   | 100                | 16%     | 84%    |
| Coincidence between the midline of the face with the midline of the dental arch | 100                | 66%     | 34%    |

individual and can be sustained. The posed smile is reliably repeatable. On the computer screen, a grid, or smile mesh, employs horizontal and vertical lines to measure 11 attributes of a smile. Therefore, it was suggested that the photographic analysis of an unstrained posed smile might be used as a standard dental record and hence, it was used in this study as a method of standardization of photographs.<sup>13</sup> In the present study, the analysis was carried out with the help of sophisticated software known as Digimizer® image analysis software that allows precise manual measurements as well as automatic object detection with measurements of object characteristics.

As per the research done by various authors,<sup>9,14,15</sup> it has been concluded that there is significant predominance of presence of parallelism between these structures, which reported that the parallelism between these two lines creates a general sense of harmony and a horizontal improvement in the esthetics of the face. Facial beauty is based on standard esthetic principles that involve proper alignment, symmetry, and proportion of face.<sup>10-12</sup>

In the present study also, the parallelism of the incisal plane with the interpupillary line was also checked and the significant predominance of presence of parallelism between these structures corroborates with the concepts defended by Latta et al<sup>14</sup> and Malafaia et al<sup>5</sup> who have reported that the parallelism between these two lines presents generalized symmetry and is of esthetic value in context to an esthetic smile. Similarly, Malafaia et al<sup>5</sup> also suggested that the dentofacial harmony is essential to obtain adequate esthetics and a successful treatment. The aim of their study was to analyze the existence of polar symmetry, obtained by two parallel lines, one along the pupils and another along the incisal edge of the upper central incisor teeth. The study had concluded that there is a correlation between the pupils and the tangent with the incisal edge of the maxillary central incisors. All these studies help the prosthodontist to assess the esthetics for a patient; these studies act as basic guidelines but not very rigid rules. The various authors<sup>5,15</sup> used three commonly used anatomic landmarks, nasion, tip of the nose, and tip of the philtrum to measure the midline of the face. The primary function of the anterior teeth in maxillary arch is to fulfil the esthetic needs. An improper placement of the midline makes it impossible to balance the elements on either side of it.<sup>16</sup> Frush and Fisher<sup>17</sup> in their classical study had suggested that the vertical long axis of the midline is more critical than mediolateral position, provided that the central incisor midline is parallel to the facial midline. Cardash et al<sup>18</sup> recommended that the anterior tooth midline be placed coincidentally with the midline of the face. The authors also recommended that the detection of deviation can be done better on the photographs rather than detection in the patient, as the

face is mostly constantly moving. According to the golden proportion, beauty of the face depends on alignment, symmetry, and proportion.<sup>19</sup> It was found in the current study that there was about 66% coincidence of facial and maxillary midline, while 34% showed none coinciding and the deviation was about 1.3 mm on average. During this study, nasion, center of philtrum, and pogonion were used to determine the facial midline.<sup>20</sup>

The smile arc is the relationship between a hypothetical curve drawn along the edges of the maxillary anterior teeth and the inner contour of the lower lip in the posed smile.<sup>21-23</sup> Within the limitations of this study, the conclusions drawn were that the most common smile arc is the convex smile arc and the maximum amount of tooth exposure is in a convex smile type. Teeth length plays a role in facial contouring and hence, should be taken into consideration during an esthetic makeover of a patient. An esthetically pleasing smile also depends on the amount of visible gingiva (gingival display). Thus, in the present study analysis was done in the Digimizer software for evaluating the gingiva visibility between the zenith of the gingiva of maxillary central incisors and the inferior border of the maxillary lip. The gingival display was measured as gingival display present or gingival display absent, and the result stated 16% of the subjects showed gingival display during a posed smile.

## CONCLUSION

Within the limitation of the study, it could be concluded that in smile design, the interpupillary line should be parallel with the incisal plane as it creates a general sense of harmony and horizontal improvement in the esthetics of the face.<sup>3,6</sup> Similarly, the dental midline should coincide the facial midline, or they should at least be parallel to each other to avoid canting – a major design flaw in natural or restored dentition. Also, the smile line should be parallel to the lower lip curvature and the gingival display while smiling should be slightly visible.<sup>9</sup> These components of the smile should be considered not as rigid boundaries, but as artistic guidelines to help prosthodontists treat individual patients who are today, more than ever, highly aware of smile esthetics.

## REFERENCES

1. Simon J. Using the golden proportion in aesthetic treatment: a case report. *Dent Today* 2004 Sep;23(9):82, 84.
2. Levin EI. Dental esthetics and the golden proportion. *J Prosthet Dent* 1978 Sep;40(3):244-252.
3. Soares GP, Valentino TA, Lima DAN, Paulillo LAM, Silva FAP, Lovadino JR. Esthetic analysis of the smile. *Braz J Oral Sci* 2007 Jan;6(21):1313-1319.
4. The Academy of Prosthodontics. Glossary of prosthodontic terms. *J Prosthet Dent* 2005 Jul;94(1):10-84.

5. Malafaia FM, Garbossa MF, Neves AC, DA Silva-Concilio LR, Neisser MP. Concurrence between interpupillary line and tangent to the incisal edge of the upper central incisor teeth. *J Esthet Restor Dent* 2009 Oct;21(5):318-322.
6. Spear F. The esthetic management of dental midline problems with restorative dentistry. *Compend Contin Educ Dent* 1999 Oct;20(10):912-914, 916, 918.
7. Morley J, Eubank J. Macroesthetic elements of smile design. *J Am Dent Assoc* 2001 Jan;132(1):39-45.
8. Al-Johany SS, Alqahtani AS, Alqahtani FY, Alzahrani AH. Evaluation of different esthetic smile criteria. *Int J Prosthodont* 2011 Jan-Feb;24(1):64-70.
9. Townsend CL. Resective surgery: an esthetic application. *Quintessence Int* 1993 Aug;24(8):535-542.
10. Thompson LA, Malmberg J, Goodell NK, Boring RL. The distribution of attention across a talkers face. *Discourse Processes* 2004 Jul;38(1):145-168.
11. Garber AD, Salama AM. The esthetic smile-diagnosis and treatment. *Periodontol* 2000 1996 Jun;11(1):18-28.
12. Ackerman JL, Ackerman MB, Brensinger CM, Landis JR. A morphometric analysis of the posed smile. *Clin Orthod Res* 1998 Aug;1(1):2-11.
13. Wolfart S, Menzel H, Kern M. Inability to relate tooth forms to face shape and gender. *Eur J Oral Sci* 2004 Dec;112(6):471-476.
14. Latta GH Jr, Weaver JR, Conkin JE. The relationship between the width of the mouth, interalar width, bizygomatic width, and interpupillary distance in edentulous patients. *J Prosthet Dent* 1991 Feb;65(2):250-254.
15. Habbu NS, Nadgir DV, Joshi N, Murali R. Interpupillary distance as a guide for the selection of upper anterior teeth. *Int J Dent Sci* 2010 Jul;9(1):1-6.
16. Yarlalagadda SK, Srinath HP, Amarnath GS, Gangadhar M. A survey of observable deviation of facial and anterior tooth midline and comparison between men and women subjects in Bangalore east population. *IJRID* 2013 Jan-Feb; 3(1):1-6.
17. Frush JP, Fisher RD. The dynesthetic interpretation of the dentogenic concept. *J Prosthet Dent* 1958 Jul;8(4):557-581.
18. Cardash HS, Ormanier Z, Laufer BZ. Observable deviation of the facial and anterior tooth midlines. *J Prosthet Dent* 2003 Mar;89(3):282-285.
19. Eskelsen E, Fernandes CB, Pelogia F, Cunha LG, Pallos D, Neisser MP, Liporoni PC. Concurrence between the maxillary midline and bisector to the interpupillary line. *J Esthet Restor Dent* 2009 Feb;21(1):37-41.
20. Miller EL, Bodden WR Jr, Jamison HC. A study of the relationship of the dental midline to the facial median line. *J Prosthet Dent* 1979 Jun;41(6):657-660.
21. Dong JK, Jin TH, Cho HW, Oh SC. The esthetics of the smile: a review of some recent studies. *Int J Prosthodont* 1999 Jan-Feb;12(1):9-19.
22. Sarver DM. The importance of incisor positioning in the esthetic smile: the smile arc. *Am J Orthod Dentofacial Orthop* 2001 Aug;120(2):98-111.
23. Tjan AH, Miller GD, The JG. Some esthetic factors in a smile. *J Prosthet Dent* 1984 Jan;51(1):24-28.