10.5005/jp-journals-10019-1014
ORIGINAL RESEARCH

Preparation and Use of Fibrin Composite as a Hard Tissue Graft Material: An Animal Study

[1]Baburajan Kandasamy, [2]Padmanabhan TV, [3]Sridhar R

[1]Professor and Head, Department of Prosthodontics, Indira Gandhi Institute of Dental Science, Pilaaiyarkuppam, Puducherry, India

[2]Professor and Head, Department of Prosthodontics, Sri Ramachandra Dental College, Chennai, Tamil Nadu, India

[3]Professor, Department of Prosthodontics, Chettinad Dental College and Research Institute, Kanchipuram, Tamil Nadu, India

Correspondence: Baburajan Kandasamy, Professor and Head, Department of Prosthodontics, Indira Gandhi Institute of Dental Science, Pilaaiyarkuppam, Puducherry, India, e-mail: baburajankandasamy@gmail.com

ABSTRACT

As the saying goes—without the wall or base, no treasure of art can be incorporated! Alveolar ridge forms the basic infrastructure for a successful denture. But resorption is inevitable sequelae of extraction.

Various graft materials have been used to improve the alveolar ridge. Hydroxyapatite is the most commonly used bone graft material. The main disadvantage of hydroxyapatite is the particle displacement leading to inadequate ridge form.

Fibrin and collagen have been used as sealants in many surgeries. So it is prudent to combine fibrillar collagen and hydroxyapatite and utilize this material as an effective graft.

The objective of this study is to study the usefulness of fibrin-fibrillar collagen hydroxyapatite composite as a graft material for the repair of experimentally created bony defects.

Keywords: Hydroxyapatite, Fibrin, Collagen.

INTRODUCTION

Surgical improvement of the denture bearing area and the surrounding tissue offers an exciting and demanding challenge in prosthodontics. Various graft materials have been tried to improve the residual alveolar ridge.

Hydroxyapatite has been used for alveolar ridge augmentation for many years. It bears close crystal and chemical remembrance to bone mineral and dental enamel.[1] It is a hard tissue implant material that interacts with and may ultimately become an integral part of living bone tissue.[2] The main disadvantage of hydroxyapatite is the particle displacement, i.e. particle extension through delicate mucosa.[3]

Fibrin has been used as a sealant for many years in the field of surgery.[4-7] Fibrillar collagen, an alloplast, constitutes about 30 to 40% of protein and 90% of organic matrix of bone in the human body. Collagen has a low antigenicity and its rate of degradation can be controlled by varying its cross-linkage by either ultraviolet and gamma irradiation or by treating it with aldehyde.[3]

So, it is prudent to combine fibrillar collagen and hydroxyapatite and utilize this material as an effective graft in dentistry.

The objective of this animal study is to study the usefulness of fibrin-fibrillar collagen hydroxyapatite composite as a hard tissue graft material for the repair of experimentally created bony defects.

MATERIALS AND METHODS

Selection of Animals

One-year-old male rabbits weighing about 1500 gm were selected for the study. The size of the sample was 12. The rabbits were divided equally into two groups. Group I served as a control. Group II was used to check the osteogenic property of fibrin composite. In order to standardize the rearing up of all the rabbits and practically of the same age, they were bought from the same supplier on the same day.

Preparation of Fibrin Composite

Fibrin Preparation

The crude fibrin from the slaughter house was washed thoroughly under running water to remove their blood clots and treated with 0.5 M sodium acetate solution to remove the remaining blood stains. The resultant material was bleached with 20 ml of hydrogen peroxide solutions (30%V/V) per liter at pH 8 (the pH was adjusted with 0.1 N sodium hydroxide solution). The bleached fibrin was removed from the bleaching bath, washed thoroughly with cold running water and ground into pulp using a mixer. It was then powdered.

Fibrillar Collagen Preparation

Bovine tibial bones were collected from slaughter house and cut into 2 × 2 inch pieces in a prebreaker. Later the bone pieces were powdered in a pulverize. The bone powder was demineralized on 0.6 M HCL for 5 to 6 days. The demineralization is ensured by radiography. Acetic acid 0.5 M was added to this matrix and stirred overnight at 4°C. The solution was centrifuged and the supernatant solution (A) was stored. The residue was extracted with pepsin (1 mg/ml) for about 12 hours and then centrifuged and the supernatant solution (B) was stored and the residue were heated at

50 to 60°C with 0.5 M acetic acid for 8 hours and centrifuged and supernatant (C) was separated. All the supernatants were pooled in 0.05 M acetic acid. It was later lipholized and stored.

Preparation of Hydroxyapatite

Tibial bones of cattle were collected from the slaughter house and the adhering tissues were removed with a knife. The proximal and distal ends were cut with a hand saw and bone marrow was extruded using a stainless steel wire. Later, the bone pieces were crushed in a bone crusher into a 2 × 2 inch pieces. Then the crushed bones were incinerated at 300°C for half an hour. The incinerated bones were heated at 900°C for 2 hours. Later, the bones were powdered in a pulverizer and sieved to get granules measuring 75 to 150 microns. The material was heated with steam under pressure for 30 minutes repeatedly till the supernatant solution was colorless (indicating complete removal of proteinaceous matter).

Preparation of Fibrin Composite

The hydroxyapatite (granular uniform) crystals with dimensions of 75 to 150 micron and Ca/P ratio of 1.67 and purified fibrin powder were mixed with the fibrillar collagen solution and made into dough. It was then extruded through a stainless steel tube. The extruded rods were dried at 45 to 50°C. It is then powdered and sealed in polythene bag. The product was then sterilized by gamma irradiation at 2 to 3 Mrads.

Surgical Technique

Preoperative Preparation

All the animals were prepared by shaving the medial aspect of hind limb. Scrubbing was done with chlorhexidine and the site was painted with provided iodine and the limb was suitably draped.

Surgical Procedure

Rabbits were anesthetized with xylazine hydrochloride 0.2 mg/kg body weight and ketamine hydrochloride, IV 1 mg/kg body weight intramuscularly. One centimeter insertion was made in the medical aspect of the right hind limb and proximal area of the tibia was exposed. Using implant motor at a speed of 5,000 to 6,000 RPM and 2.8 mm drill, a through/defect was created 1 cm distal to the tibial tuberosity.

In group I animals, the defect was not packed with any material and the flap was sutured using (3.0) silk (control). In group II animals, the fibrin composite was packed and the material was condensed using a plastic filling material and the flap was sutured using (3.0) silk (Fig. 1).

Postoperative Care

The wound was cleaned daily and Soframycin dressing was given. The rabbits were well maintained and fed with commercially available rabbit feeds and the fresh leafy vegetables at the animal house in TN Government Veterinary College.

Fig. 1: Incision in the rabbit

Evaluation of Experiment

It was decided to access the osteogenic property by the end of 3, 6 and 12 weeks.

Biochemical Analysis

Two milliliter of blood was obtained by earlobe puncture. The blood was allowed to flow freely into collection tubes and kept in a slanting position for about 1½ to 2 hours. Formation of clot and clot retraction was seen. Serum exudates was separated and used for the analysis of serum calcium by modified o-cresolphtalein complexone (OCPC) method by Mooreheared and Briggs and serum alkaline phosphatase by semi autoanalyzer.

Radiography

By the end of 3rd, 6th and 12th weeks, radiographs were taken. The exposure factors were 46 kVP at 5 MAS. The focal distance is 100 cm and thickness was 1 inch without grid.

Osteomedullography

Rabbits were anesthetized with xylazine hydrochloride and ketamine hydrochloride intramuscularly. Medial aspect of the right hind limb was prepared under aseptic procedure. Skin incision was made near the tibial tuberosity. Using a micromotor and bur measuring 1 mm a hole was drilled in the cortex 18 gauge spinal needle was fixed in the bur hole. The patency and the position of the needle in the bone marrow were assessed by infusing 2 ml heparinized normal saline 5 ml of sodium iothalamate 420 mg/ml were infused rapidly. Two radiographic exposures were made. First at the end of infusion of 3 ml and second exposure was made as the infusion was about to be over. Exposure factors were 48 kVP at 4 MAS. The film focal distance was 100 cm. Thickness was 1 inch without grid.

Histopathology

The dissected bone tissue was fixed in a 10% formalin solution for 3 days then demineralized with formalin, nitric acid mixture (formalin 10 ml, distilled water 80 ml, nitric acid 10 ml). The embedded tissues were cut into 5 to 6 micron thickness slices and were stained with hematoxylin and eosin. The stained sections were examined under light microscope using 100× and 320× magnification.

RESULTS

Biochemical Analysis

Calcium Content

The calcium contents were determined on 3rd, 6th and 12th weeks postoperatively. Calcium content is a direct measure for the extent of mineralization during bone fracture healing.

By 3rd week, the calcium contents were negligible in both the groups. The calcium contents in the fibrin composite were 76.97 and 110.80 µg/mg compared to 37.26 and 56.25 in control by the 6th and 12th week respectively. This clearly indicates the excellent osteoinductive property of fibrin composite (Graph 1).

Alkaline Phosphatase

The level of alkaline phosphatase activity was determined by the end of 3rd, 6th and 12 weeks. The alkaline phosphatase level determines the new bone formation. The alkaline phosphatase in the fibrin composite group were 5.2, 5.5 and 4 units/mg at the end of 3rd, 6th and 12th week. The alkaline phosphatase activities in the control group were 3, 3.2 and 2.5 units/mg.

The above result indicates that the alkaline phosphatase level of fibrin composite is higher than those of the control. The increase in alkaline phosphatase activity was observed prior to increased mineralization. The results also indicate that the bone formation was faster in fibrin composite than in the control group (Graph 2).

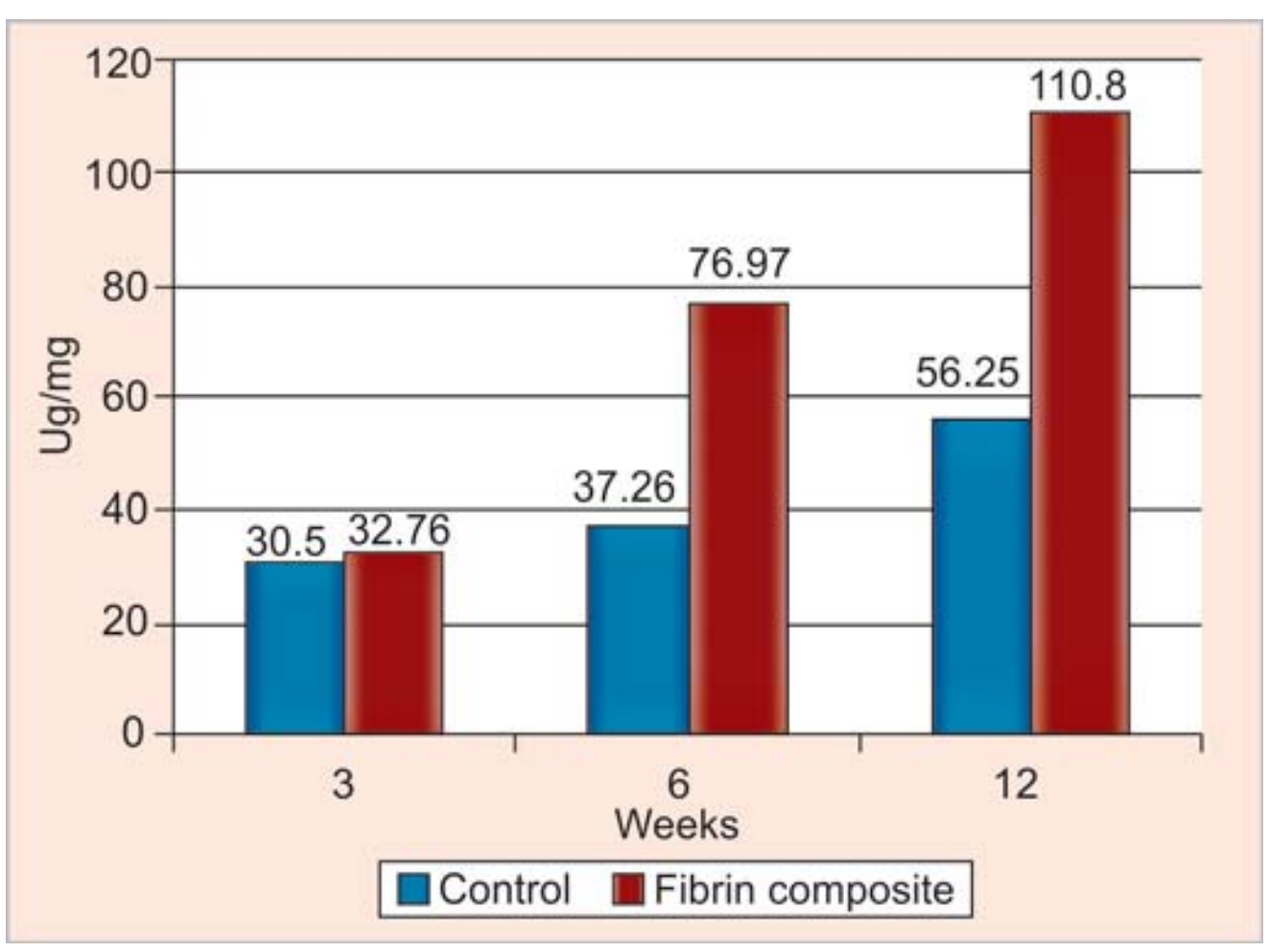

Graph 1: Biochemical analysis – serum calcium

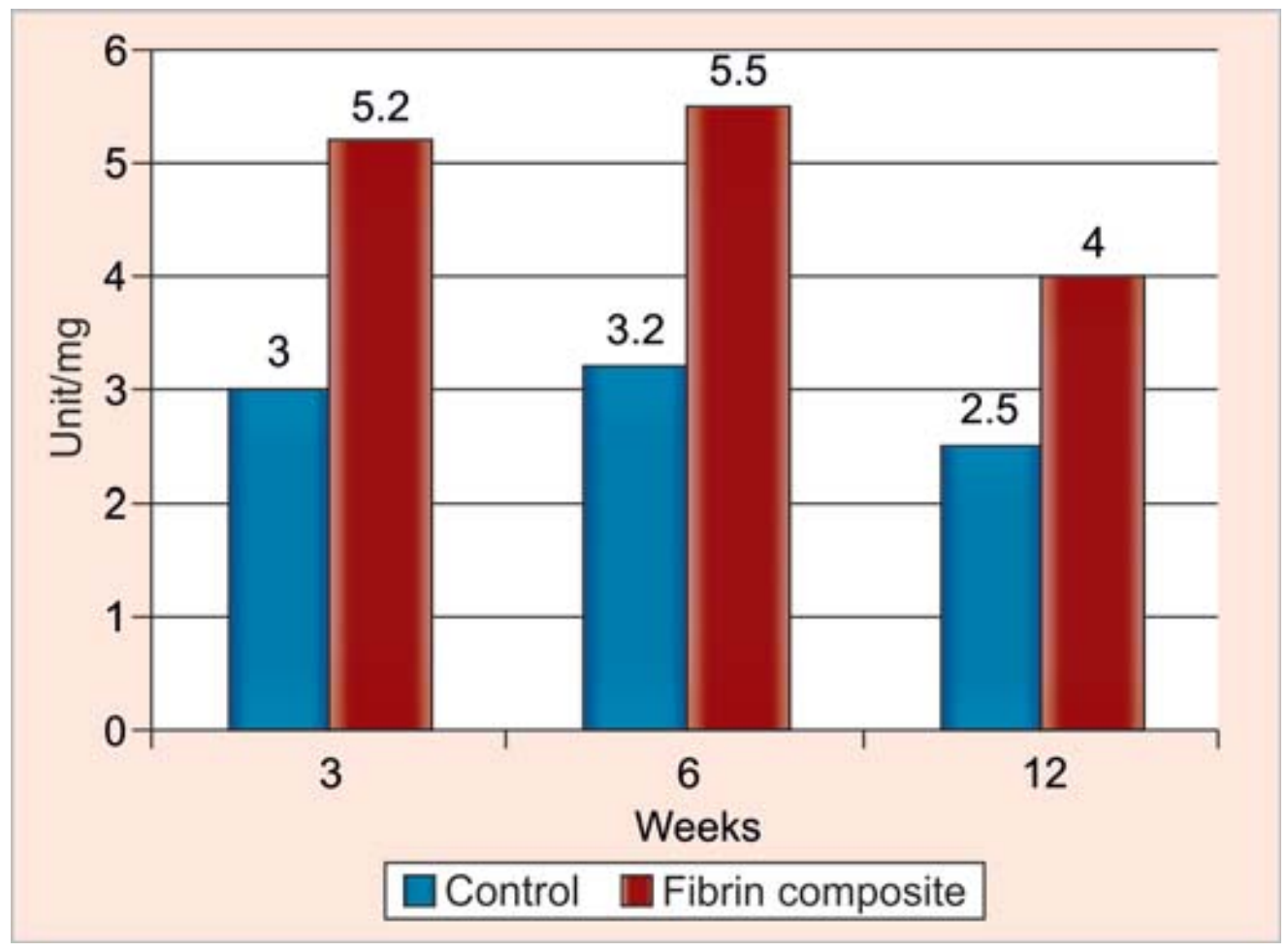

Graph 2: Biochemical analysis – alkaline phosphatase

Radiological Evaluation

Group I (Control)

The 24-hour postoperative radiographic finding revealed the site defect in all the animals. The 3rd week radiographic finding also reveals the defect with no radiodensity changes (Fig. 2). The 6th week radiographic finding also revealed no changes (Fig. 3). The 12th week radiograph reveals a slight radiodensity indicating the callous formation (Fig. 4).

Group II (Fibrin Composite)

The 24-hour postoperative radiograph revealed the presence of graft material at the site of defect in all animals. The 3rd week radiograph shows the retention of fragments in opposition; though there were no radiodentisty changes at the

Fig. 2: Radiographic evalution—3rd week (control)

Fig. 3: Radiographic evalution—6th week (control)

defect and around the graft material (Fig. 5). By the 6th week postoperative, there was increased radiodensity at the fractured ends and around the graft material indicating mild callous formation (Fig. 6) and by the 12th postoperative week, there was satisfactory callous formation between the two cortices and around the graft material which had filled the bony defect (Fig. 7).

Fig. 4: Radiographic evalution—12th week (control)

Fig. 5: Radiographic evalution—3rd week (fibrin composite)

Fig. 6: Radiographic evalution—6th week (fibrin composite)

Fig. 7: Radiographic evalution—12th week (fibrin composite)

Osteomedullography

The osteomedullography was performed in the 12th week.

Group I (Control)

The osteomedullography showed that the patency of the dye was irregular. The dye has leaked through the defect indicating that the bone healing has not taken place (Fig. 8).

Group II (Fibrin Composite)

In this group, the patency of the dye was regular and the flow of dye was also uniform throughout the medulla indicating that the bone formation has taken place (Fig. 9).

Fig. 8: Osteomedullography (control)

Fig. 9: Osteomedullography (fibrin composite)

Histopathological Analysis

Group I (Control)

After 3 weeks, the hematoma that formed initially was organized into a granulation tissue and finally fibroblast, which laid down collagen. After 6 weeks, the collagen was organized into an osteoid matrix. In the 12th week, the section showed the appearance of typical bone which was calcified and the osteocytes were seen in each individual osteon. The overall appearance at the 12th week resembled normal bone (Fig. 10).

Group II (Fibrin Composite)

In the 3rd week, well-formed osteoid matrix was seen exhibiting osteogenic activity. Numerous Haversian canals were also seen. In the 6th week, there was further increase in the osteogenic activity marked by formation of trabecular bone containing islands of mineralized bone. Typical osteons and canaliculi were predominant in the sections. After 12 weeks, there was a well-formed mature dense bone exhibiting marked reversal lines indicating maximum bone remodeling which in turn is an indicator of increase osteogenic activity (Fig. 11).

DISCUSSION

The continuous resorption of the residual alveolar ridge after extraction affects the denture stability, retention and also produces impaired masticatory efficiency and compromised esthetics.

The total amount of bone resorbed and the rate of resorption are different for each individual. They also vary greatly in the

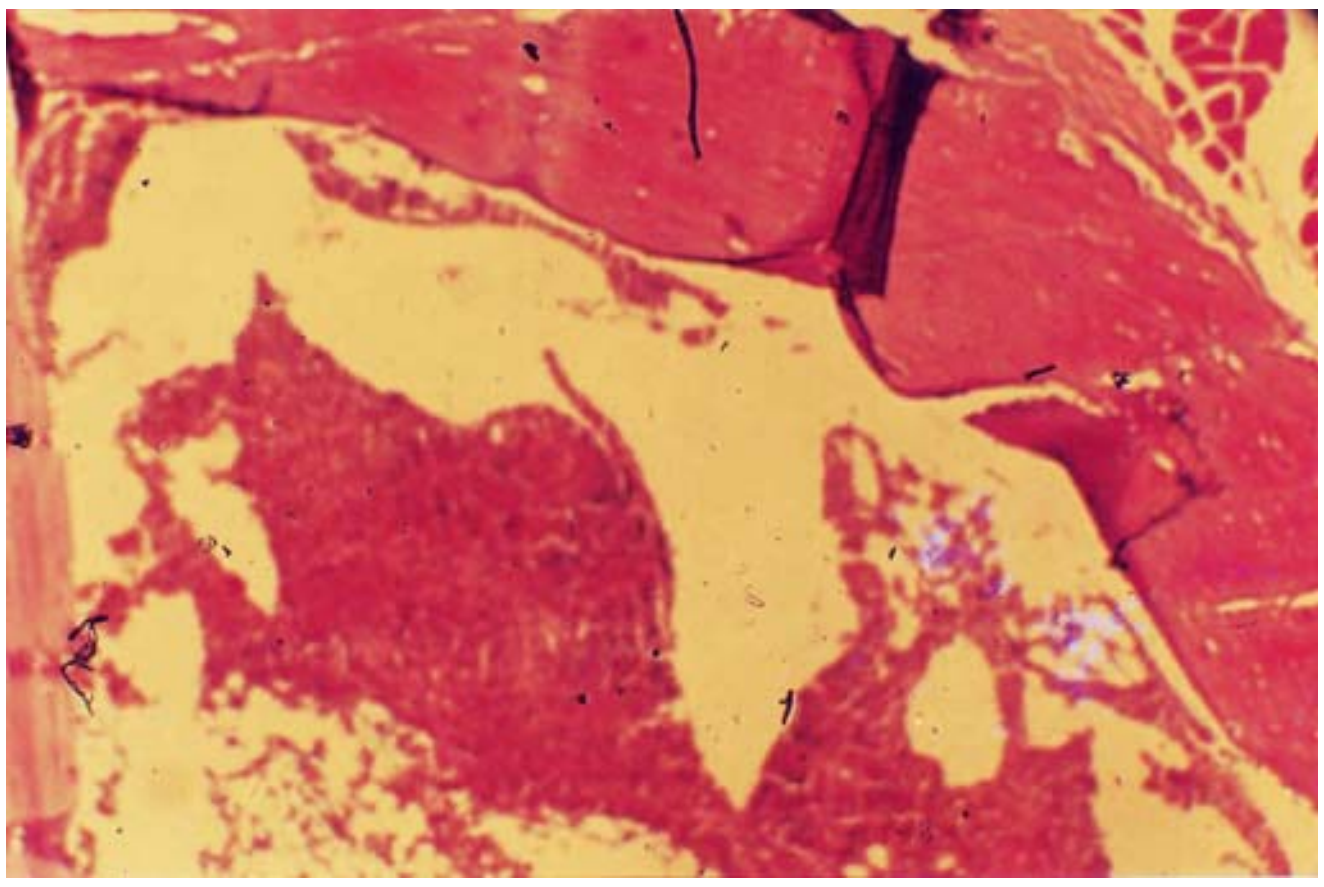

Fig. 10: Histopathology (control)

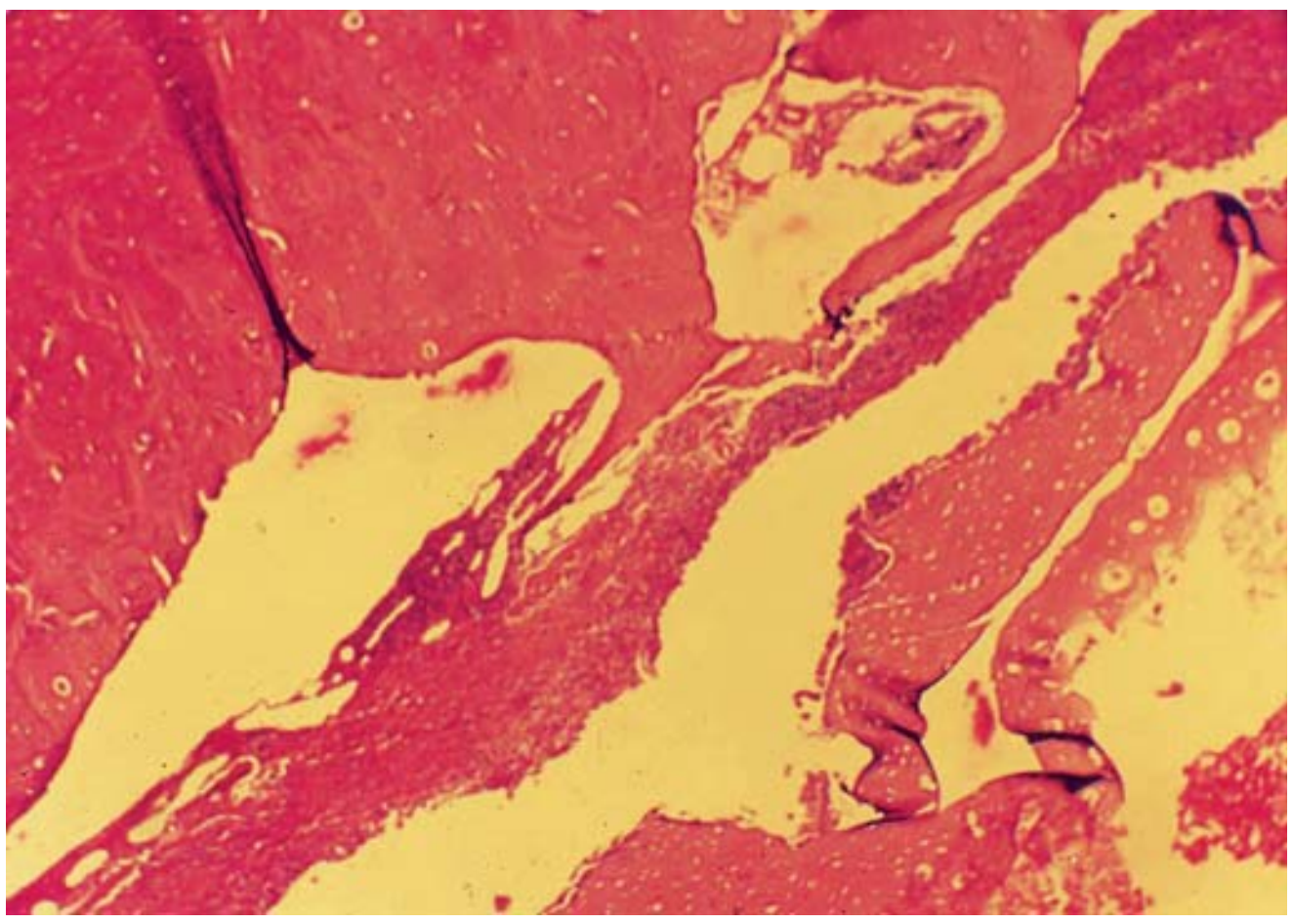

Fig. 11: Histopathology (fibrin composite)

same individuals in different locations. A direct correlation exists between alveolar ridge type and patient acceptance.[1]

Surgical improvement of the residual alveolar ridge has been an exciting and demanding challenge. Various graft materials have been tried to improve the residual alveolar ridge.[8]

Hydroxyapatite has been used to fill bone defects because of its nontoxic nature, its biocompatibility and osteoconductive property. The use of hydroxyapatite coating for metallic prosthesis has been shown to enhance host bone apposition and initial implant fixation has proved that there is a static fit.[9]

There is also historical evidence that resorbable hydroxyapatite is resorbed and replaced by woven and lamellated bone in bone cell specimens removed at 4 and 14 months postimplantation.[2]

Other histological studies have also proved that there were ultimate contact between bone matrix and hydroxyapatite with no intervening layer of tissue.[10,11]

All these studies prove that hydroxyapatite is an excellent alloplast graft material.

Unfortunately, the mechanical properties of pure hydroxyapatite in ceramic are poor. Their fracture toughness does not exceed 1.0 Mpa M ½ (Human bone 2-12 Mpa M ½) .[9]

The immobilization of hydroxyapatite granules in a bone defect has been a problem. Postsurgically, the granules have a tendency to migrate beyond the intended area. In order to prevent the migration of hydroxyapatite granules from the implant site, various methods like tubes or resorbable collagen and clay containing hydroxyapatite have been tried.[6]

Fibrin has been used as an adhesive, sealant and glue in many surgical procedures.[7] Fibrin glue has been proved to promote osteosynthesis of epithelial injuries. They have been used as a seal out in reimplantation of cartilage and osteocontra segmental in human being.[7]

Collagen is a protein content in our body. Studies have shown that collagen mixed with hydroxyapatite had favorable results.[11-13]

So, it is prudent to mix these three materials namely fibrin, collagen and hydroxyapatite to develop a new material fibrin composite which should have the advantage of all the three materials.

The alkaline phosphatase level determines the new bone formation. In the control group, the increased level of alkaline phosphatase was seen. Whereas in fibrin composite group, there was a gradual increase in 3rd and 6th week and there was a drop in the alkaline phosphatase level indicating that the new bone formation has been taken place in between 6 and 12 weeks.

The radiographic evaluation also revealed the same result. By the end of the 12th week, extensive callus formation was noted in the fibrin composite group. The result of the osteomedullography also reveals the excellent healing of the defect by the 12th week using fibrin composite.

The above results were confirmed histologically. By the end of 12th week the fibrin composite group showed well-formed mature dense bone exhibiting marked reversal lines indicating maximum bone remodeling.

CONCLUSION

Having discussed the biocompatibility and osteogenic properties, it is concluded that:

Fibrin composite can be used as a graft material for the correction of experimentally created bony defects.

However, further evaluation has to be done using this material. To be confirmatory, it should be tried in dogs and then on human beings.

ACKNOWLEDGMENTS

Dr TP Sasthry, Scientist, Department of Biomaterials, Central Leather Research Institute, Adayar, Chennai for the preparation of the materials.

Prof Dr Archibald David, MVSc. PhD, Professor of Surgery, Madras Veterinary College, Chennai for allowing to utilize their operation theater, perform the surgery, maintaining the animals, analyzing the results and utilize their library.

REFERENCES

1. Cranin AN, Satler N, Ettinger M. Hydroxyapatite for alveolar ridge augmentation: A clinical study. J Prosth Dent 1986;56: 592-99.
2. Seibert JS, Salama H. Alveolar ridge preservation and reconstruction. Periodontol 2000 1996;11:69-84.
3. Maruyama M, Ito M. In vitro properties of chitosan-bonded self hardening paste with hydroxyapatite granules. J Biomed Mater Res 1996;32:527-32.
4. Dragan JM, Zoran DP, Sasa SZ, Zoran AS, Aleksandar MS. Prevention of pocket-related complications with fibrin sealant in patients undergoing pacemaker implantation who are receiving anticoagulant treatment. Europace 2005;7(4):374-79.
5. Giampapa Vincent G, George J. Bitar use of fibrin sealant in neck contouring. Aest Surg J Nov 2002;22(6):519-25.
6. Bantauehu Sileshi, Achneck Hardean E, Lawson Jeffrey H. Management of surgical hemostasis: Topical agents. Vascular April 2, 2008:6(1):S22-28.
7. Silver Frederick H, Ming Che Warty, Pins George D. Preparation and uses of fibrin glue in surgery. J Biomater 1995;16: 891-903.
8. Kruger Gustav O. Textbook of oral and maxillofacial surgery. Volume 6; Chapter 15. Tissue Transplantation 296-332.
9. Masahhi Marn Yama, Masaaki Maruyama. Hydroxyapatite clay used to fill the gap between implant and bone. The J Bone Surge 1995;77:213-18.
10. De Lange GL, De Putter C, De Wrjs A FLJ. Histological and ultrastructural appearance of the hydroxyapatite—bone interface. J Bio Mater Res 1999;24:829-45.
11. Mangesh, Kale Purushottam. Evaluation of fibrin composite and tricalcium phosphate composite for the repair of fracture of radius with bone in goats. This is submitted to the Tamilnadu Veterinary and Animal Science University, Chennai 1998.
12. Wojcrech Suchanek, Masahiro Yoshimura. Processing and properties of hydroxyapatite based biomaterials for use and hard tissue replacement implants. J Mater Res 1998; 13(1):94-116.
13. Beime OR, Curtis Tn, Green Pan S. Mandibular augmentation with hydroxyapatite. The J Prostho Dent 1986; 55:362-67.