

# Denture Stomatitis: Treatment with Diode Laser

<sup>1</sup>Keerthana Sivakumar, <sup>2</sup>Sivakumar Palanivelu, <sup>3</sup>Sudhakar Ramalingam, <sup>4</sup>Sankaranarayanan Seshadri

<sup>1</sup>Senior Lecturer, Department of Prosthodontics, Karpaga Vinayaga Institute of Dental Sciences, Tamil Nadu, India

<sup>2</sup>Senior Lecturer, Department of Oral and Maxillofacial Pathology, Karpaga Vinayaga Institute of Dental Sciences, Tamil Nadu, India

<sup>3</sup>Reader, Department of Oral and Maxillofacial Pathology, Karpaga Vinayaga Institute of Dental Sciences, Tamil Nadu, India

<sup>4</sup>Professor, Department of Oral and Maxillofacial Pathology, Karpaga Vinayaga Institute of Dental Sciences, Tamil Nadu, India

**Correspondence:** Keerthana Sivakumar, Senior Lecturer, Department of Prosthodontics, Karpaga Vinayaga Institute of Dental Sciences, Tamil Nadu, India, e-mail: skshivashiva@yahoo.co.in

## ABSTRACT

Denture stomatitis is a relatively common oral mycotic infection occurring in partial or complete denture wearers. *Candida albicans* is one of the principal etiological factors, with number of local or systemic co-factors influencing the occurrence. While an array of agents are involved in the occurrence and progression of the lesion, one could not expect monotony in the treatment modality. Spectrum of treatment modes have been practised to manage denture stomatitis, which include proper maintenance of oral and denture hygiene to systemic antifungal medication. Here we present a case of denture stomatitis, successfully treated with diode laser with 6 months follow-up.

**Keywords:** Denture stomatitis, Diode laser, *Candida albicans*.

## INTRODUCTION

Denture stomatitis (DS) is a chronic candidal infection associated with 60 to 65% of denture wearers.<sup>1,2</sup> *Candida albicans* is the principal causative organism of DS.<sup>1</sup> Other than *Candida* and presence of denture, multiple predisposing factors are involved in the occurrence and progression of DS. Local factors, such as poor oral hygiene, ill fitting denture, hyposalivation and systemic factors, such as long-term antibiotic therapy, usage of corticosteroids, diabetes, impaired immunity, and malignancy may incline an individual to DS.<sup>2,3</sup> It is commonly encountered in the palatal mucosa covered by maxillary denture than mandibular denture and shows female sex predilection.<sup>4,5</sup> Clinically, DS is classified into three types type I: Pin-point hyperemic lesions (localized simple inflammation), type II: Diffuse erythema involving a part or entire denture covered mucosa (generalized simple inflammation), type III: Granular surface (inflammatory papillary hyperplasia).<sup>6</sup> Maintenance of good oral and denture hygiene, and correction of ill-fitting denture usually results in remission of infection.<sup>7,8</sup> Laser beam, cryosurgery, electrosurgery and scalpel surgery are successfully practised in treating the infection, especially for type II and type III infection.<sup>6,9,10</sup> Due to adverse effect and possibilities of intolerance, usage of antifungal therapy is discouraged or reserved for debilitated or systemically compromised patients.<sup>6</sup>

## CASE REPORT

A 75-year-old male reported to Outpatient Department of Karpaga Vinayaga Institute of Dental Science with complaint

of burning sensation in mouth for past three and half months. History reveals he was completely edentulous and wearing complete upper and lower denture for past 6 months. Medical history was not contributory. On intraoral examination, an erythematous patch was observed on posterior part of the hard and soft palate (Fig. 1). Alveolar ridge of maxilla and mandible and other mucosal areas appeared normal. Clinically, it was diagnosed as denture stomatitis involving palatal mucosa. Exfoliative cytology was performed and stained with periodic acid-Schiff (PAS) method, which showed fungal hyphae with inflammatory and squamous cells (Fig. 2). The case was diagnosed as type II denture stomatitis. The patient has been treated with 980 nm wavelength diode laser to ablate the palatal lesion in low power setting of 2 watt for 15 seconds (Fig. 3).

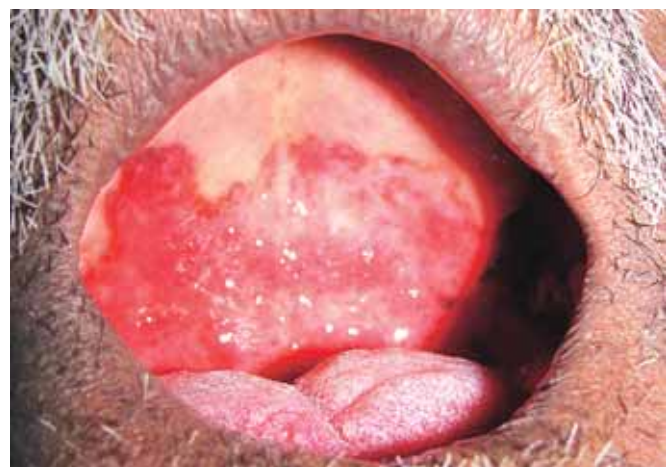

Fig. 1: Intraoral photograph showing erythematous palatal mucosa

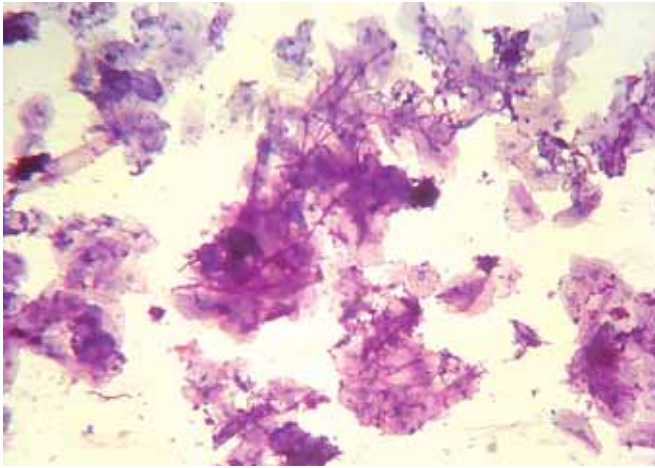


Fig. 2: Fungal hyphae

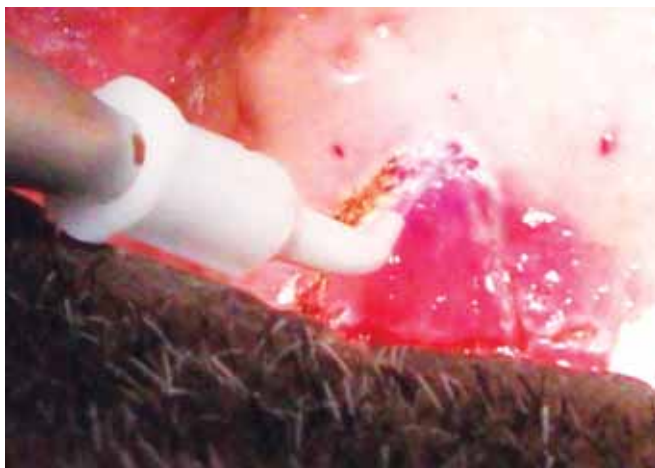

Fig. 3: Application of laser beam

The application was repeated two times per visit and entire treatment was completed within two visits. The patient was advised about the importance of oral and denture hygiene and educated regarding denture usage. One week later the complete resolution of infection was observed. With 6 months follow-up the patient was free of infection and he was comfortable in wearing denture (Fig. 4). The patient was advised to report periodically.

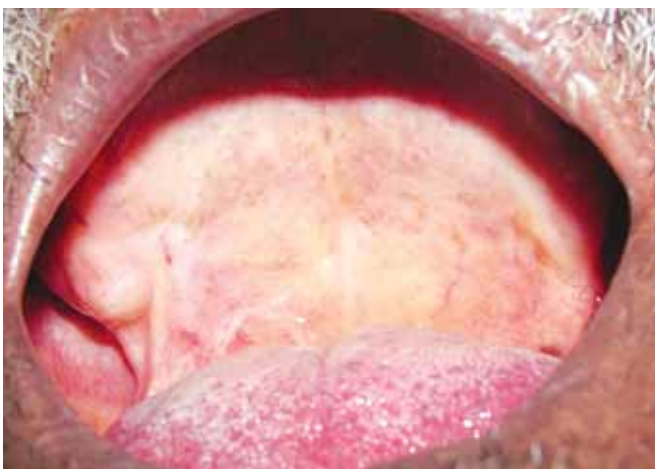

Fig. 4: Complete resolution of lesion

## DISCUSSION

Denture stomatitis is the most common infectious disease encountered in denture wearers.<sup>11</sup> Most of the patients are unaware of the lesion present (asymptomatic) and they are diagnosed during routine clinical examination; burning sensation, diffuse erythema of the involved mucosa with hyperemic points, halitosis are some of the clinical features of denture stomatitis.<sup>6,7,12</sup> Treatment of denture stomatitis varies according to nature of predisposing factors involved and the clinical types.<sup>8</sup> Maintenance of good oral and denture hygiene appears to be the foremost important criteria to be followed. Treatment of DS with antifungal agents is effective and complete resolution of lesion will occur within 12 to 14 days.<sup>1</sup> Usage of antifungal agents has its own drawbacks, like continuous use for atleast 2 to 4 weeks, irregular medication will results in resistance to candida species and relapse of lesion will occur. Chlorhexidine, the most commonly used disinfectant should not be used along with nystatin because the former may inhibits its antifungal capacity.<sup>1</sup> Therefore, antifungal agents should be reserved for more extensive lesion involving other oral mucosal surfaces and in debilitating patients.<sup>6</sup>

Treatment with laser appears to be obliging than using antifungal or scalpel surgery. Laser beam not only helps in ablation of superficial candida contaminated epithelial surface but also prevent inflammation of adjacent normal mucosa.<sup>13</sup> Postoperative prescription of antibiotic or nonsteroidal antiinflammatory drugs (NSAID) will not be required since the delivered laser energy appears to be bactericidal and viricidal. This may prevent the reinfection or secondary infection by bacteria.<sup>13</sup> The neuron sealing effect of lasers aids in adequate pain control.<sup>13</sup> In our case, clinically, it was diagnosed as type II denture stomatitis and treated with diode laser. The patient showed complete resolution of infection within a week. The patient was examined periodically up to 6 months and showed no recurrence of infection.

## CONCLUSION

Treatment of denture stomatitis with laser beam not only helps in patient from redundant usage of antifungal drugs but also the sterile environmental procedure negates the need for postoperative antibiotic. Lesser bleeding area makes the surgical procedure (especially for type III) easier and effective. Hence, usage of laser beam in such cases appears to be quite appreciating and promising not only for the patients but also to the dental professionals.

## REFERENCES

1. Salerno C, Pascale M, Contaldo M, Esposito V, Busciolano M, Milillo L. Candida-associated denture stomatitis. *Med Oral Patol Oral Cir Buccal*—ahead of print.
2. Mattos BSC, De sousa AA, De magalhaes MH, Brito E dias R. *Candida albicans* in patients with oronasal communication and obturator prostheses. *Braz Dent J* 2009;20(4):336-40.

3. Cannon RD, Holmes AR, Mason AB, Monk BC. Oral candida: Clearance, colonization, or candidiasis. *J dent Res* 1995;74(5): 1152-61.
4. Lynch DP, Tenn M. Oral candidiasis: History, classification, and clinical presentation. *Oral surg Oral med Oral Pathol* 1994; 78:189-93.
5. Monroy TB, Maldonado VM, Martinez FF, Barrios BA, Quindos G, Vargas LOS. *Candida albicans*, *staphylococcus aureus* and *streptococcus mutans* colonisation in patients wearing dental prosthesis. *Med Oral Patol Oral Cir Buccal* 2005;10:E27-39.
6. Zarb GA, Bolender CL. Prosthodontic treatment for edentulous patients. Complete dentures and implant-supported prostheses (12th ed). Mosby 2004.
7. Yilmaz HH, Aydin U, Ipek C. *Gulhane Tip Dergisi*: Is denture stomatitis related with denture hygiene? *Gulhane Tip Dergisi* 2002;44(4):412-14.
8. Akpan A, Morgan R. Oral candidiasis. *Postgrad Med J* 2002; 78:455-59.
9. MK, Abdel-Meguid SH, Mokhtar SA, Rizk SA. Effect of low-energy laser application in the treatment of denture-induced mucosal lesions. *Marei J Prosthet Dent* 1997;77(3):256-64.
10. Maver-Biscanin M, Mravak-Stipetic M, Jerolimov V, Biscanin A. Fungicidal effect of diode laser irradiation in patients with denture stomatitis. *Laser Surg Med* 2004;35(4):259-62.
11. Cenci TP, Delbelcury AA, Crielaard W, Tencate JM. Development of candida-associated denture stomatitis: New insights. *J Appl Oral Sci* 2008;16(2):86-94.
12. Neville BW, Damm DD, Allen CM, Bouquot JE. *Oral and maxillofacial pathology* (3rd ed). WB Saunders, Philadelphia 2004.
13. Naveenkumar J, Bhaskaran K. Denture-induced fibrous hyperplasia: Treatment with corbondioxide laser and a two-year follow-up. *Indian J Dent Res* 2007;18(3):135-37.