

Overdenture Abutments under a Fixed Partial Denture: Case Report of a Preventive Prosthodontic Approach

¹Saumyendra Singh, ²Naina Talwar, ¹Niraj Mishra, ³Pooran Chand

¹Assistant Professor, Department of Prosthodontics, CSM Medical University, Lucknow, Uttar Pradesh, India

²MDS Student, Department of Prosthodontics, CSM Medical University, Lucknow, Uttar Pradesh, India

³Associate Professor, Department of Prosthodontics, CSM Medical University, Lucknow, Uttar Pradesh, India

Correspondence: Saumyendra Singh, Assistant Professor, Department of Prosthodontics, CSM Medical University, Lucknow Uttar Pradesh, India, e-mail: saumyendrasingh@rediffmail.com

ABSTRACT

The use of overdenture abutments under removable partial dentures to preserve alveolar bone and provide support is well established, but there is little evidence of their use under fixed partial dentures. There exist a variety of clinical situations in which teeth or roots with questionable prognosis cannot be utilized as abutments for fixed partial dentures. In such situations these teeth/roots can be preserved under fixed prosthesis to provide vertical support and delay bone loss. The following report describes technical considerations, advantages and limitations of this treatment modality.

Keywords: Overdenture abutments, Fixed partial dentures, Support, Alveolar bone preservation.

INTRODUCTION

Preventive prosthodontics emphasizes the importance of any procedure that can delay or eliminate future prosthodontic problems. Retention of roots to serve as overdenture abutments is a logical method of preventive prosthodontics. It offers several advantages from biologic as well as functional perspectives.¹ However, little has been published in literature regarding the use of such abutments under fixed partial dentures (FPD).²⁻⁵

The following report provides an insight into how endodontically treated roots can be preserved under the pontics of a FPD to provide support and preserve underlying alveolar bone at the same time.

CASE REPORT

History and Examination

A 50-year-old male patient visited the department with the chief complaint of difficulty in eating and food lodgement since the past 5 years. He had a history of squamous cell carcinoma of tongue, for which wide excision of the right side of tongue alongwith the removal of right supraomohyoid lymph nodes was done 6 years back. A split skin graft was given to reconstruct the excised tissues. The mobility of tongue and associated structures reduced dramatically thereafter. Radiotherapy sessions followed surgery which resulted in reduction of the salivary output, probably leading to the carious involvement of multiple teeth (no. 17, 16, 31, 32, 41, 42, 43,

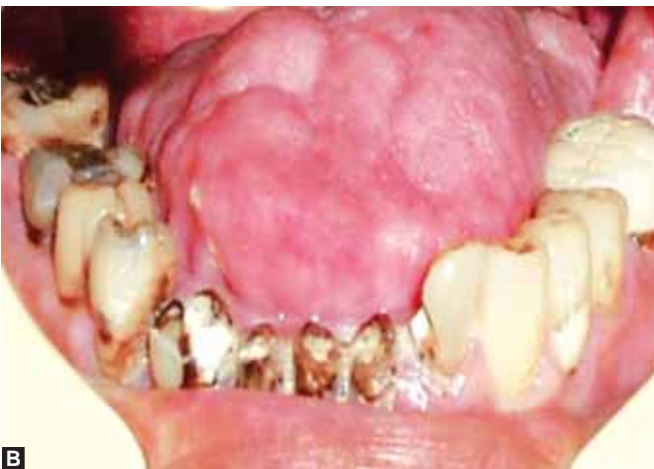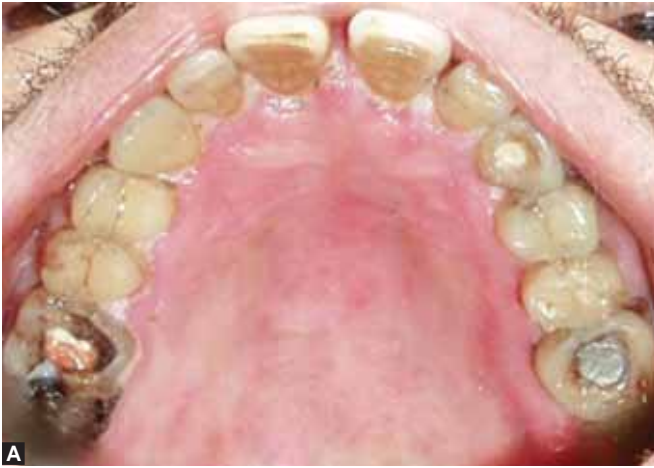46 and 47). While teeth no. 32, 31, 41, 42 and 43 were extensively decayed, teeth no. 31, 41 and 42 had hardly any existing coronal tooth structure (Figs 1A to 2). This had led to compromised esthetics. The only missing tooth was no. 37 and its extraction socket had not healed completely since the past 2 years. Cervical abrasions were generalized and a few teeth had been restored previously, namely teeth no. 23, 24, 25 and 34. A faulty porcelain fused to metal (PFM) crown was present on tooth no. 36 with open margins. The right quadrant showed a reverse curve of spee due to decay of mandibular molars and subsequent supraeruption of maxillary molars. The gingiva in mandibular anterior region was edematous due to food impaction around the broken down teeth. Oral hygiene maintenance was fair.

Radiographic Examination

OPG revealed that teeth no. 17, 16, 23, 26, 36, 32, 31, 41, 42, 43, 44, 46, 47 were endodontically treated. The canals were well obturated without evidence of any obvious periapical pathology (Fig. 3).

Treatment Planning

After weighing the relative advantages and disadvantages of various treatment options that existed, it was decided to fabricate a seven unit metal ceramic FPD using teeth no. 33, 32, 43 and 44 as FPD abutments and teeth no. 31, 41 and 42 as overdenture abutments under the pontics of the FPD.



Figs 1A and B: Intraoral preoperative view of (A) maxillary arch, (B) mandibular arch

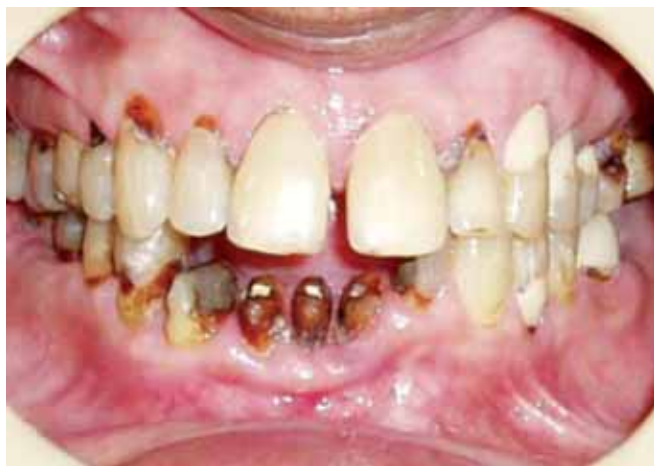

Fig. 2: Frontal preoperative view

The step by step definitive procedure was as follows:

1. Two sets of study casts were made for records and treatment planning. One set of maxillary and mandibular casts were articulated using quick mount face bow (Whip Mix Corp, USA).
2. On the articulated casts, mock wax-up was done to correct the occlusal plane on the right side conforming the curve of spee. Putty index was made over the mock wax-up to serve as a guide for reduction of teeth.

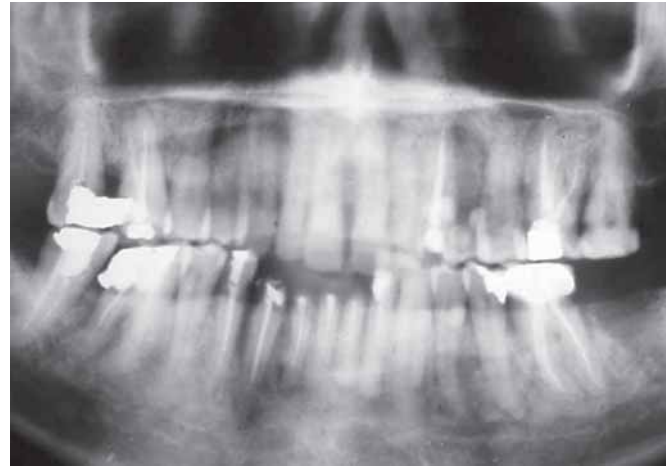


Fig. 3: Preoperative orthopantomogram

3. Reduction of teeth no. 31, 41 and 42 was done till the gingival level (to serve as overdenture abutments). Post and core preparation of tooth no. 32 [fibre post with composite core (Bioloren, Ammdent, India)] and tooth no. 43 [custom made cast post and core (Harmony, Williams, Amherst, NY)] was performed followed by preparation of teeth no. 32, 33, 43 and 44 to serve as abutments for the future metal ceramic FPD (Fig. 4).
4. Dome shaped metal copings (Harmony, Williams, Amherst, NY) were fabricated over the overdenture abutments with small post extensions in the canal space for retention⁶ (Fig. 5).
5. A seven unit metal ceramic FPD (Willceram Y, Williams, Amherst, NY) was fabricated with pontics in no. 31, 41 and 42 region and retainers on teeth no. 33, 32, 43, 44. Cervical abrasions on unrestored teeth were filled with restorative glass ionomer cement (Ketac molar easymix, 3M ESPE AG, Germany) to prevent further decay. The faulty crown on no. 36 was removed followed by giving full metal crowns on teeth no. 17, 16, 26, 36, 46, 47 (Harmony, Williams, Amherst, NY) to establish a favorable plane of occlusion using the mock wax-up fabricated previously (Fig. 6).

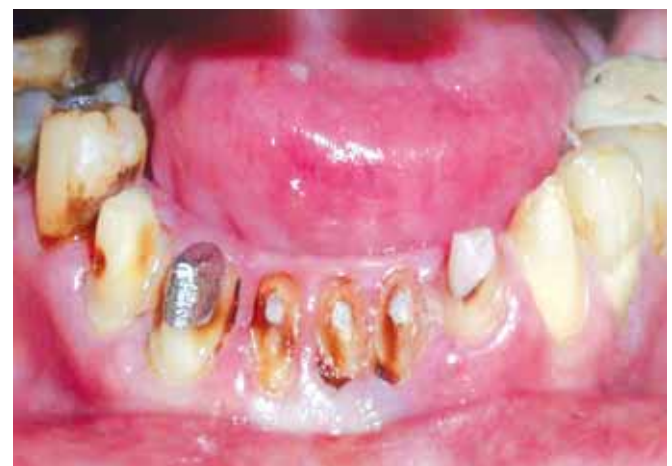

Fig. 4: Reduction of overdenture abutments

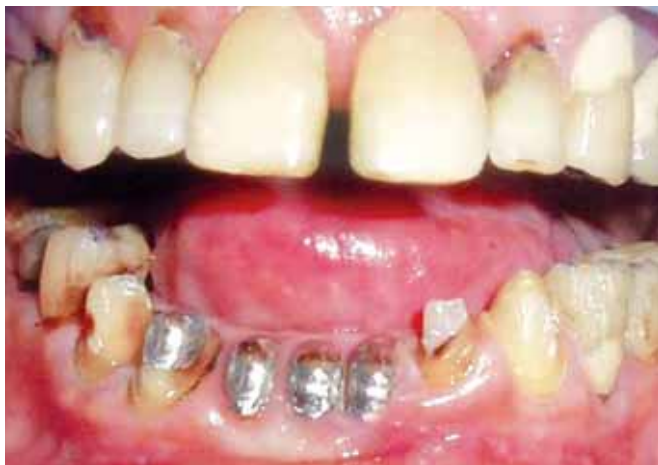

Fig. 5: Metal copings on overdenture abutments and reduction of conventional abutments

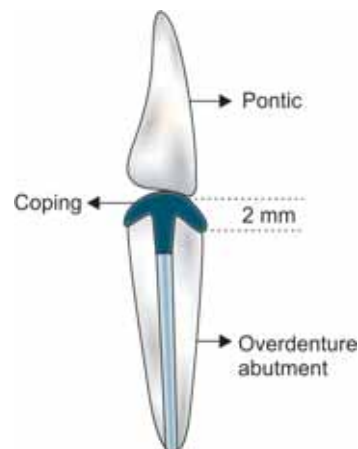


Fig. 7: Relationship of gingival surface of pontic with the overdenture abutment

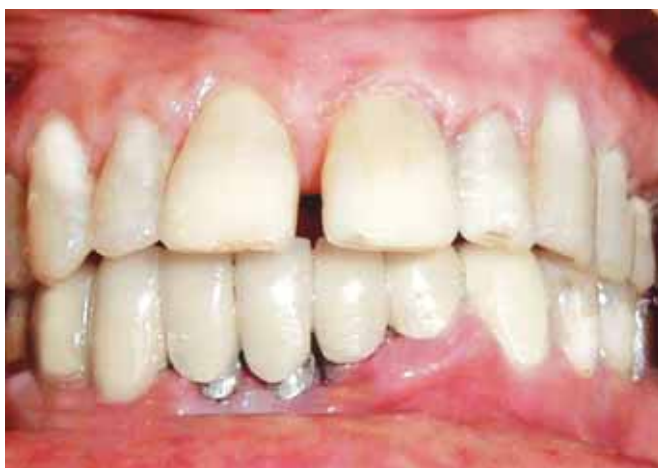
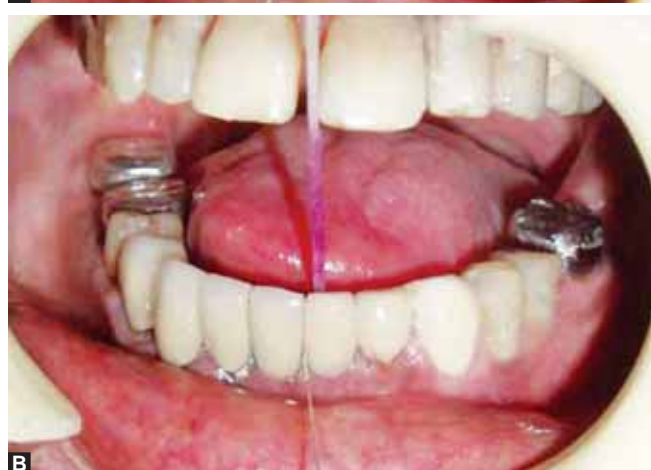
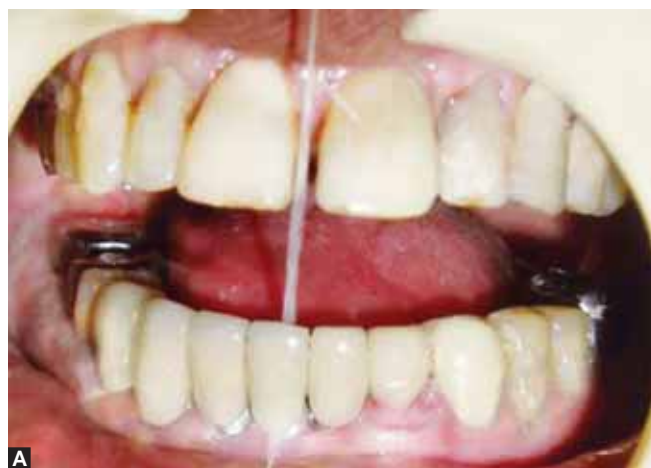Fig. 6: Metal ceramic FPD

6. The pontics were made with a modified ridge lap design to contact the underlying copings passively on the labial half, and free of contact on the lingual side. This contact aided transmission of some occlusal forces without hindering cleansibility. The pontic margins were kept 2 mm short of the coping margins (Fig.7).
7. The patient was advised to regularly use interproximal brushes and dental floss for cleansing the contact area between overdenture abutments and pontics (Figs 8A and B). Fluoride mouth rinses (Senquel AD, Dr Reddy's Laboratory Ltd, India) were also prescribed to the patient.⁷
8. Patient was kept on a fortnightly recall to ensure rigorous hygiene maintenance specially in the mandibular anterior region.

DISCUSSION

A variety of treatment options existed for this clinical situation. A Kennedy's class IV removable partial denture using teeth no. 31, 41 and 42 as overdenture abutments was eliminated because of the shallow lingual vestibule, reduced mobility of the tongue and susceptibility to mucosal ulcerations (because



Figs 8A and B: Demonstration of easy cleansibility in the overdenture abutment area

of the previous radiation therapy). The lingual plate major connector in this situation would have had insufficient occlusogingival height to provide rigidity and interfered with tongue movement.⁸ Extraction of teeth no. 31, 41 and 42 was ruled out because patients who have received radiotherapy are poor healers prone to osteoradionecrosis (as was evidenced in this case—a 2-year-old nonhealed socket was present at the extraction site of tooth no. 37). Post and core build-up of teeth

no. 31, 41 and 42 was not done because of absence of ferrule around the decayed teeth. Therefore, it was decided to prosthetically rehabilitate the patient utilizing the roots of teeth no. 31, 41 and 42 as overdenture abutments beneath the FPD.

There are a number of clinical situations (as here) in which compromised teeth cannot serve as abutments for FPD. In such conditions these abutments may be preserved under the pontics to provide additional support (the forces on such abutments are less, and in a more or less vertical direction). They also preserve alveolar bone which would otherwise be resorbed if extractions of such teeth were planned.⁹⁻¹¹

Few examples where FPD overdenture abutments may be used are: (1) complications including root fractures requiring extensive surgery to provide post and core build-up and lack of adequate ferrule, (2) hemisected molars which are too weak or difficult to restore as a traditional FPD abutment, (3) under a cantilevered prosthesis to distribute excessive stress on the main abutment, (4) periodontally weakened teeth and (5) malplaced implants which may be rendered useless as an FPD abutment but may be usable as an overdenture abutment.¹²

It was decided to place copings over the overdenture abutments to prevent further decay. The undersurface of the pontic overlying these abutments was designed to fulfil both esthetic and biologic requirements. The gingival margin of the pontic was kept 2 mm short of the coping margin on both the facial and lingual surface to permit ease of cleansing. The gingival surface was designed as modified ridge lap and embrasure areas were created to provide access for home care hygiene measure and professional prophylactic care.¹³ If in such a case the maxillary anterior region was involved, the pontic could cover the entire coping on the labial aspect and be free of contact on the palatal aspect, to permit hygiene maintenance. The contact of the pontic with the underlying overdenture abutments provided better support for the long span FPD by distributing occlusal forces.

A complication that can occur with this treatment is possibility of extraction of an overdenture abutment in the future. This may be accomplished by removing the FPD and extracting the involved root. Once the residual ridge below the pontic has remodeled, the pontic may be modified by adding composite to the tissue surface, in the shape of modified ridge lap pontic. Another complication which may occur is the carious involvement of the overdenture abutments at the margin of the coping.¹⁴ This can only be prevented by stringent hygiene implementation.

CONCLUSION

The advantage of this treatment plan was that the patient was provided satisfactory esthetics, function and comfort while preserving alveolar bone and minimizing stress on the conventional FPD abutments (which were already weakened by caries and endodontic treatment). In the limited options available, we chose the most viable alternative. A year has passed since delivery of the prosthesis and due to excellent standards of hygiene maintenance, there have been no incidence of secondary caries or gingival inflammation in the mandibular anterior region.

REFERENCES

1. Brewer AA, Morrow RM. Overdentures (1st ed). St Louis: CV Mosby 1973.
2. Brill N. Adaptation and the hybrid prosthesis. *J Prosthet Dent* 1955;5:811-24.
3. Miller PA. Complete dentures supported by natural teeth. *J Prosthet Dent* 1958;8:924-28.
4. Morrow RM, Powell JM, Jameson WS, Jewson CG, Rudd KD. Tooth supported complete dentures: An approach to preventive prosthodontics. *J Prosthet Dent* 1969;21:513-22.
5. Becker CM, Kaldahl WB. An overdenture technique designed to protect the remaining periodontium. *Int J Periodont Restorative Dent* 1984;4:28-41.
6. Brewer AA, Morrow RM. Overdentures (2nd ed). St Louis: CV Mosby 1980.
7. Derkson GD, MacEntee MM. Effect of 0.4% stannous fluoride gel on the gingival health of overdenture abutment. *J Prosthet Dent* 1982;48:23-26.
8. Henderson D. Major connectors for mandibular removable partial denture. *J Prosthet Dent* 1973;30:532-48.
9. Warren AB, Caputo AA. Load transfer to alveolar bone as influenced by abutment designs for tooth-supported dentures. *J Prosthet Dent* 1975;33:137-46.
10. Thayer HH, Caputo AA. Effects of overdentures upon remaining oral structures. *J Prosthet Dent* 1977;37:374-81.
11. Crum RJ, Rooney GE. Alveolar bone loss in overdentures: A 5-year study. *J Prosthet Dent* 1978;40:610-13.
12. Becker CM, Kaiser DA. Overdenture abutments for fixed partial dentures. *J Prosthet Dent* 2000;84:366-69.
13. Becker CM, Kaldahl WB. Current theories of crown contour margin placement and pontic design. *J Prosthet Dent* 1981;45:268-77.
14. Toolson LB, Smith DE. A 2-year longitudinal study of overdenture patients: Incidence and control of caries on overdenture abutments (Part I). *J Prosthet Dent* 1978;40:486-91.